

LEIPZIG
INTERVENTIONAL
COURSE
2019

LIN C

22 – 25 January 2019

Trade Fair Leipzig, Hall 2
Messe-Allee 1, 04356 Leipzig,
Germany

Guide to Live Case
Transmissions

www.leipzig-interventional-course.com

LINC



Get the LINC 2019 app for iPhone, iPad, and iPod



Programme

sort the LINC programme by day, room, or faculty member and view selected lectures the following day.



Exhibitors

view the list of all LINC exhibitors and find their location on our interactive floorplan.



Live Cases

sort the LINC live cases by day, center, or operator and review your favorite live cases the following day.



General Information

get all important informations about and around LINC to organise your personal LINC visit.



Faculty

find the schedule of your favourite faculty members.



Get the LINC app now!
With a QR reader or
visit the app store.



Guide to Live Case Transmissions

During the Leipzig Interventional Course 2019 more than 80 interventional and surgical live cases are scheduled to be performed and transmitted to the auditorium. The aim of this booklet is to give you an overview about the live case schedule and to provide a practical guide through the procedures.

We hope for your understanding that with respect to the clinical needs of the patients changes of the schedule may occur. Furthermore, the anticipated procedural steps are just an outline of the procedure. Depending on the discretion of the operator the procedural strategy or the choice of material may vary.

LEIPZIG
INTERVENTIONAL
COURSE
2019

L I N C

Tuesday,
January 22, 2019

Case 01 – LEI 01: male, 75 years (M-K)

Calcified SFA-occlusion right

Operators: A. Schmidt, M. Ulrich

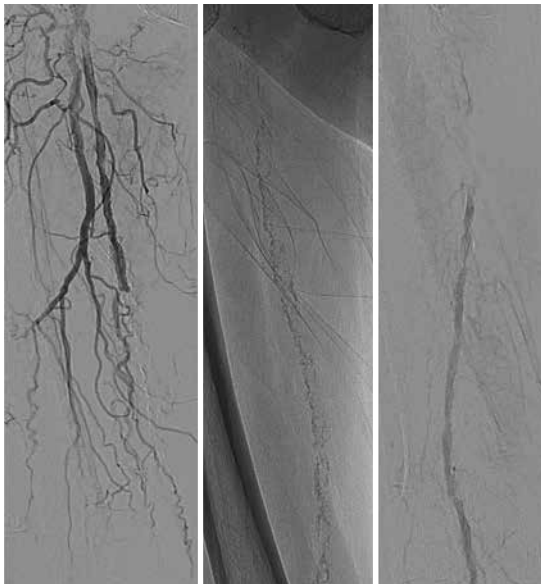Clinical data: Severe claudication right calf, walking capacity 100 meters,
ABI right 0.54, Rutherford class 3
PTA both EIA 10/2014 and left SFA 12/2014
CAD, AMI 02/2014
Mild renal impairment

Risk factors: Arterial hypertension, hyperlipidemia, former smoker

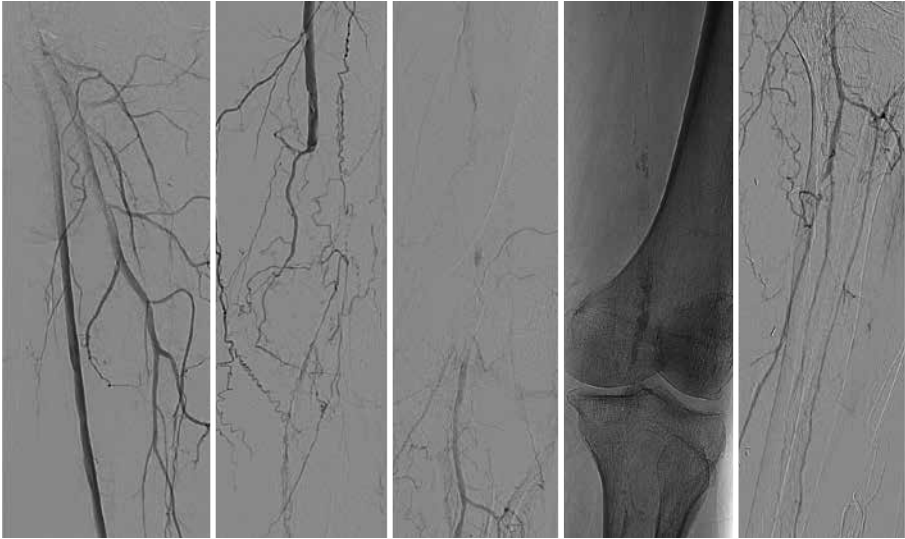
Procedural

steps:

1. **Left groin retrograde and cross-over approach**
 - 0.035" SupraCore guidewire 190 cm (ABBOTT)
 - 7F 40 cm Balkin Up&Over sheath (COOK)
2. **Guidewire passage**
 - Command 18 and Armada 18 balloon (ABBOTT) or
 - 0.035" Radiofocus soft angled guidewire, 260 cm (TERUMO)
3. **In case of failure to pass the CTO**
 - GoBack™ Crossing Catheter (UPSTREAM PERIPHERAL)
4. **PTA**
 - 4.0 – 6.0 mm Armada 35 balloon (ABBOTT)
 - Conquest high pressure balloon on indication (BARD)
5. **Stenting**
 - 5.0 or 6.0/150 mm Supera Interwoven Selfexpanding Nitinol stent (ABBOTT)



Case 02 – LEI 02: male, 73 years (W-H)

Calcified CTO of the left distal SFA and left popliteal artery**Operators:** S. Bräunlich, A. Fischer**Clinical data:** PAOD Rutherford III left, painfree walking distance 100 m, ABI left: 0,5
CAD, ICM (EF 32%), AMI 2014 and 12/2018, CABG 2014, PTCA 12/18
Renal impairment**Risk factors:** Arterial hypertension,
diabetes mellitus type 2 with angio- and neuropathy, hyperlipidemia**Procedural steps:**

1. **Right groin retrograde and cross-over approach**
 - 0.035" SupraCore guidewire 190 cm (ABBOTT)
 - 7F 40 cm Balkin Up&Over sheath (COOK)
2. **Guidewire passage and PTA**
 - Command 18 and Armada 18 balloon (ABBOTT) or
 - 0.035" Radiofocus soft angled guidewire, 260 cm (TERUMO) and 4.0/120 mm Armada 35 balloon (ABBOTT)
 - 5.0/40 mm Armada 35 balloon (ABBOTT)
3. **Stenting**
 - 5.0/150 mm Supera Interwoven Selfexpanding Nitinol stent (ABBOTT)

Case 03 – LEI 03: male, 74 years (P-V)

Occlusion of the right SFA

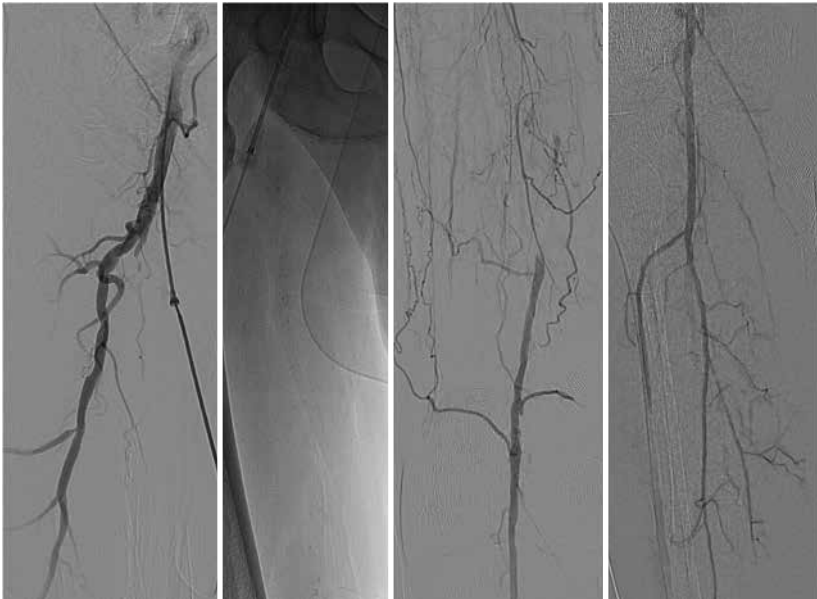
Operators: S. Bräunlich, M. Matschuck

Clinical data: PAOD Rutherford 3, walking capacity 100 m, ABI right 0.55, left 0.6
Failed recanalisation attempt of the right SFA 08/12 elsewhere
Renal impairment grade 2

Risk factors: Arterial hypertension, former nicotine abuse (20PY), hyperlipidemia

Procedural steps:

- 1. Left groin and cross-over approach**
 - Judkins Right 5F diagnostic catheter (CORDIS/CARDINAL HEALTH)
 - 0.035" SupraCore guidewire 30 cm (ABBOTT)
 - 6F 40 cm Balkin Up&Over sheath (COOK)
- 2. Guidewire passage of the occlusion**
 - 0.035" Halfstiff Terumo 260 cm (TERUMO)
 - 0.035" QuickCross support catheter, 135 cm (PHILIPS)
- 3. PTA with scoring balloon**
 - 4/40 mm AngioSculpt PTA scoring balloon (PHILIPS)
- 4. PTA with DCBs**
 - Stellarex 5.0/120 mm DCBs (PHILIPS)



Case 04 – LEI 04: female, 76 years (M-R)

Chronic total occlusion right SFA

Operators: M. Ulrich, M. Matschuck

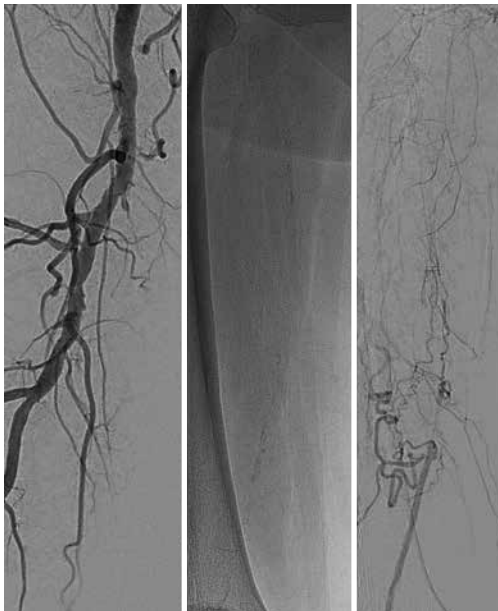Clinical data: Severe claudication both calves, walking capacity 20 meters
Obesity, renal impairment G3, ICM, myocardial infarction 2009
ABI right: 0.53 and left: 0.64

Risk factors: Arterial hypertension, former smoker

Angiography: 11/2018: long SFA-occlusions both sides, moderate calcification

Procedural steps:

1. **Left groin retrograde and cross-over approach**
 - IMA-diagnostic 5F catheter (CORDIS/CARDINAL HEALTH)
 - 0.035" angled soft Radiofocus guidewire, 190 cm (TERUMO)
 - 0.035" SupraCore guidewire, 190 cm (ABBOOTT)
 - 6F Balkin Up&Over sheath, 40 cm (COOK)
2. **Passage of the occlusion of the right SFA**
 - 0.035" Radiofocus angled stiff guidewire, 260 cm (TERUMO)
 - 0.035" TrailBlazer support catheter, 135 cm (MEDTRONIC)
 - Exchange to 0.018" SteelCore guidewire (ABBOTT)
3. **PTA with DCBs**
 - 5.0 mm Chocolate balloon (MEDTRONIC)
 - 6.0/120 mm In.Pact Pacific DCB (MEDTRONIC)
4. **Stenting on indication**
 - Complete Selfexpanding Nitinol stent (MEDTRONIC)



Case 05 – NY 01: female, 75 years, (S-C)

Severe diffuse left SFA disease with distal occlusion

Operators: P. Krishnan, V. Kapur

Clinical data: Left leg claudication x 6 months (< 3 blocks)
Failed exercise therapy and a trial of Cilostazol
ABI (R/L) 0.92/0.71

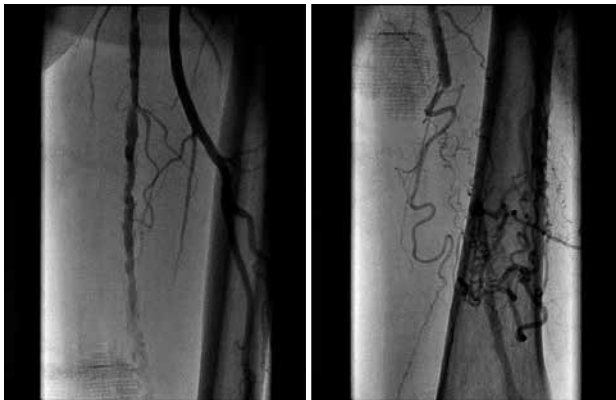
Risk factors: Type 2 DM, HTN, dyslipidemia

Duplex: Suggestive of distal left SFA occlusion

Procedural

steps:

1. **Right CFA access**
 - Micropuncture sheath (COOK)
2. **Access sheath**
 - 6F 45 cm crossover Destination sheath (TERUMO)
3. **Antegrade lesion crossing**
 - 0.035" stiff angled guidewire (TERUMO)
4. **Embolic protection**
 - Emboshield Nav 6 (4-7) filter deployment (ABBOTT)
5. **Ultrasound**
 - Vision PV 0.14 intravascular ultrasound (PHILIPS)
6. **Atherectomy**
 - Directional atherectomy, Hawk M (MEDTRONIC)
7. **Angioplasty**
 - Drug coated balloon angioplasty IN.PACT Admiral balloon (MEDTRONIC)
8. **Stenting**
 - Stent scaffold for severe flow limiting dissection



Post cancer IVC and iliac vein occlusion with impending ulceration

Operators: G. O'Sullivan, M. Mullin

Patient data: 26 year old male, initially presented with a scrotal mass (July 2017), and was found to have metastatic testicular cancer. Subsequent CT demonstrated large retroperitoneal lymph nodes and IVC; 3 months into treatment he developed right iliofemoral and left common iliac venous thrombosis. He was treated with therapeutic Innohep (Figure 1). Unfortunately, whilst on treatment, he suffered a further left lower limb DVT in October 2017. Gradually worsening swelling both legs, worse on the right.

The patient was referred to the IR clinic in December 2018 with bilateral lower limb swelling and signs of chronic venous hypertension (Figure 2).

Clinical data: In complete remission from original cancer. Worsening right leg swelling – impending ulceration; frequent sick leave; barely able to hold down a job. Works as a foreman in a yard.

Present state: Bilateral lower limb post thrombotic syndrome and chronic venous hypertension December 2018. MRV demonstrates an occluded and fibrotic infrarenal IVC and common iliac veins with reconstitution at the level of the common femoral vein (Figures 3–5). The patient had also developed numerous abdominal wall collateral veins.

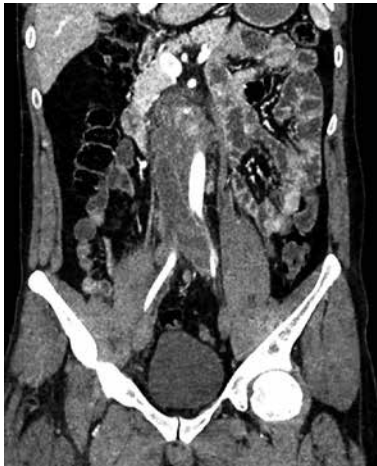

Fig. 1: 2017 Thrombosed inferior vena cava with extension into common iliac veins

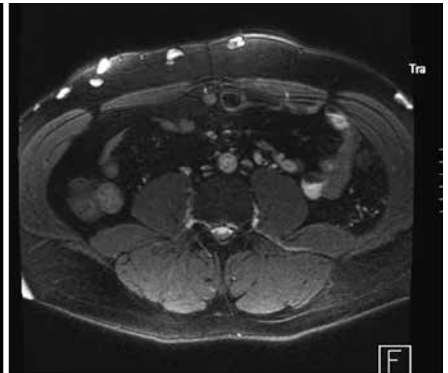


Fig. 2: 2018 Tiny IVC and numerous collaterals

Case 06 – GAL 01 (cont.): male, 26 years

Procedural steps:

1. Pre-op: Bloods: FBC, U&E, Coag; MR venogram, general anaesthetic, urethral catheter
2. Right internal jugular access 10F sheath; bilateral common femoral vein puncture using 5F microaccess kit (COOK) – attempt to cross from neck initially; 7500uIV Heparin
3. Crossing catheter (CXI/Crosser/Rubicon) to get from above to below or visa versa. MUST USE FREQUENT LATERAL PROJECTIONS TO CONFIRM WIRES LIE ANTERIOR TO VERTEBRAL BODIES.
4. Biplanar venography (AP and LAO for left, AP and RAO for right) and IVUS (Volcano, PHILIPS) evaluation
5. High pressure balloon predilatation (Atlas, BARD) 14 mm kissing throughout IVC and Iliac veins to groins
6. Stents Veniti Vici (BOSTON SCIENTIFIC) 14_120 kissing IVC and CIVs_ Wallstents 14_90 (BOSTON SCIENTIFIC) into groins_ NORMAL to NORMAL
7. Post dilatation to same diameter and pressure
8. IVUS and venography
9. In case of rupture back up 12F sheaths and Gore Viabahn 13 mm_100
10. Standard post op care_ boots_ stockings_ maintain full anticoagulation; Colour Doppler Day 1 and CTV at 6 weeks

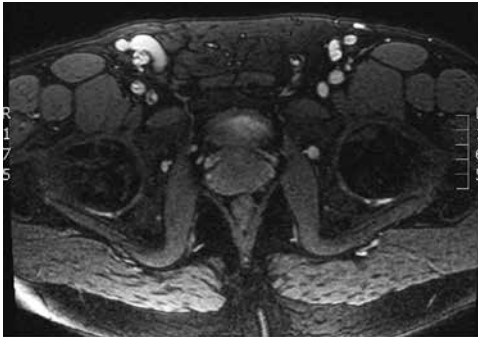


Fig. 3: 2018 Synechiae in R EIV CFV_ left side looks less abnormal

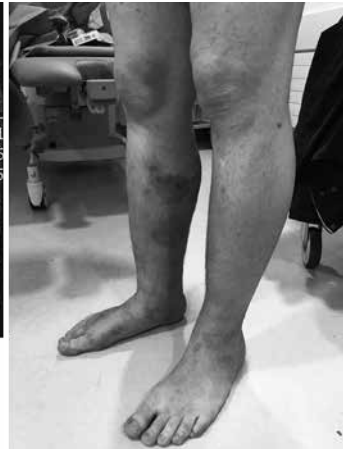

Fig. 4: Swollen legs; impending R leg ulceration

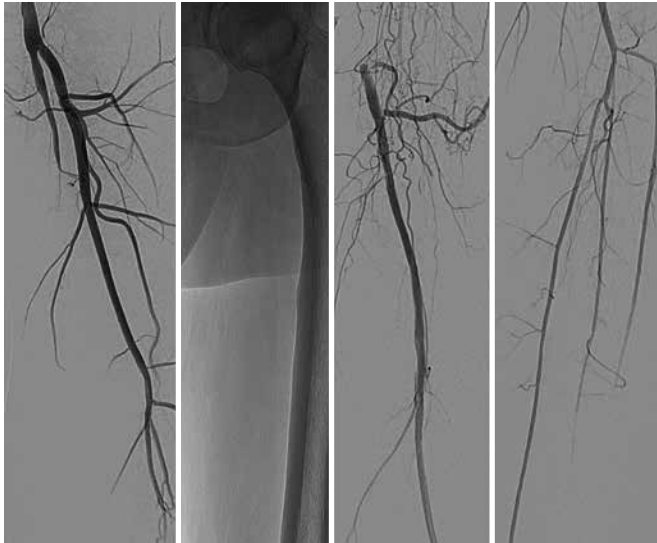Case 07 – LEI 05: male, 64 years (P-W)

Chronic CTO left SFA, CLI

Operators: S. Bräunlich, M. Ulrich

Clinical data: Critical limb ischemia left, ulceration dig 4, Rutherford class 5
Severe claudication left calf, walking capacity 50–100 meters,
PTA/stenting left EIA 11/2018
ABI left: 0.45

Risk factors: Diabetes mellitus type 2, arterial hypertension, former smoker



Procedural steps:

1. **Right femoral access and cross-over approach**
 - 6F 45 cm cross-over sheath Fortress (BIOTRONIK)
2. **Passage of the occlusion left SFA**
 - 0.035" Radiofocus angled stiff guidewire, 260 cm (TERUMO)
 - 0.035" CXC support catheter, 135 cm (COOK)

In case of failure guidewire passage from antegrade:
3. **Retrograde approach via distal SFA**
 - 9 cm 20 Gauge spinal needle (BD)
 - 0.018" V-18 Control guidewire, 300 cm (BOSTON SCIENTIFIC)
 - 4F 10 cm Radiofocus introducer (TERUMO)
 - Passeo 18 4.0/40 mm balloon, 90 cm (BIOTRONIK)
4. **PTA**
 - Passeo 18 Ballon 5 x 150 mm (BIOTRONIK)
 - 5 mm Passeo 18 Lux DCB (BIOTRONIK)
5. **Stenting on indication, spot-stenting**
 - Pulsar 18-T3 stent (BIOTRONIK)

Case 08 – NY02: male, 61 years (D-V)

Calcified left superficial femoral artery

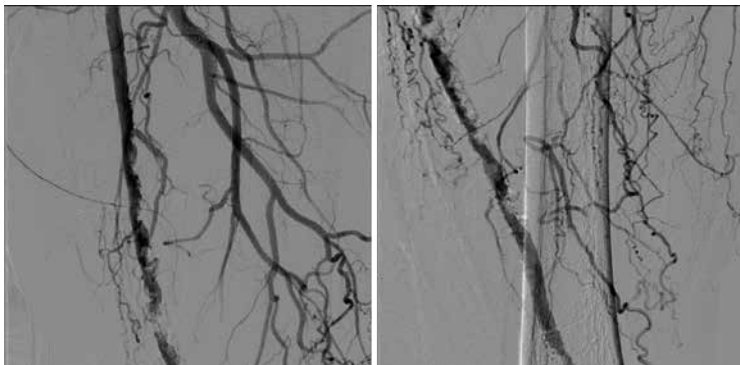
Operators: P. Krishnan, G. Dangas, V. Kapur

Clinical data: Progressively worsening claudication of left lower extremity x 6 months
Failed exercise therapy and Cilostazol 100 mg twice a day
ABI 0.88/0.64

Risk factors: Type 2 DM, HTN, dyslipidemia
Remote TIA

Procedural steps:

1. **Right CFA access**
 - Micropuncture sheath (COOK)
2. **Access sheath**
 - 7F 45 cm Ansel cross-over sheath (COOK)
3. **Lesion crossing**
 - 0.35" stiff angled guidewire (TERUMO)
supported by 0.35" Navicross catheter (TERUMO)
4. **Embolic protection**
 - Emboshield Nav 6 (4-7) filter deployment (ABBOTT)
5. **Ultrasound**
 - Vision PV 0.14 intravascular ultrasound (PHILIPS)
6. **Lithoplasty**
 - Shockwave Intravascular Lithotripsy (SHOCKWAVE INC.)
7. **Stenting**
 - Supera 6.0 x 150 mm stent (ABBOTT)



Case 09 – ZUE 01: male, 39 years (FJ-C)

Woven nitinol stent for chronic total occlusion of common femoral vein

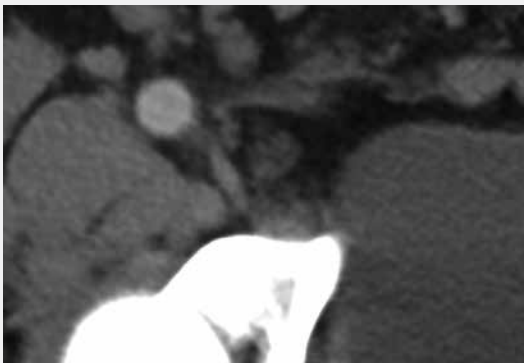
Operators: N. Kucher, D.-D. Do

Clinical data: Severe post-thrombotic syndrome right leg
History of provoked deep venous thrombosis left leg 2009

Present state: Villalta score: 12 points
Heterozygote Faktor-V Leiden mutation

Duplex: Right leg: chronic thrombosis of common femoral and femoral vein
Patent iliac veins

- Procedural steps:**
1. Analgosedation propofol, fentanyl; ultrasound-guided access: of the size and location of metastases.
 2. Lesion examination with selective venography in two orthogonal views, deep femoral vein imaging using balloon occlusion venography of common femoral vein, provisional IVUS
 3. Passage of femoral vein occlusion using stiff angled guidewire 0.035", Astato 0.018" 30 g tip load, angled 0.035" CXI support catheter
 4. Balloon angioplasty up to 12 mm high pressure of common femoral vein, provisional cutting balloon up to 8 mm
 5. Placement of Blueflow stent (14 x 100 mm or 14 x 150 mm) likely from the jugular approach
 6. Postdilatation high pressure of Blueflow up to 14 mm (Atlas Gold, BARD)
 7. Final venograms and assessment of peak flow velocity in common femoral vein by Duplex sonography



Case 10 – GAL 02: female, 45 years (K-B)

Left ilio-femoral acute deep vein thrombosis

Operators: G. O'Sullivan

Clinical data: 2 week history of low back pain, radiation to left groin,
1 week history of a painful swollen leg
No specific risk factors

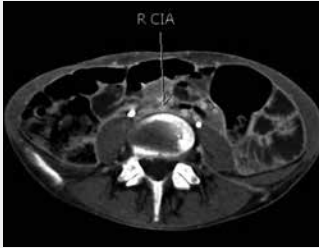


Fig. 1: classic left iliac vein compression syndrome between overlying right common iliac artery and anterior aspect sacrum

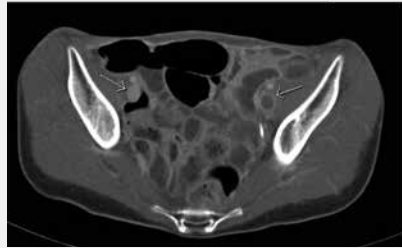


Fig. 2: note swollen left external iliac vein compared with normal right

Procedural steps:

1. Pre op: CTPA to assess for pulmonary embolus CTV for intra-abdominal veins US to confirm popliteal vein is patent
2. Initially supine; ultrasound guided puncture right internal jugular vein; Capturx device (STRAUB MEDICAL) in position – get the goalkeeper in place!
3. Now turn prone; ultrasound guided puncture of left popliteal vein; 10F sheath; 5000u IV Heparin
4. 65 cm torqueable catheter and 180 cm glidewire; once past lesion exchange for 0.025" wire
5. Aspirx Thrombectomy catheter (STRAUB MEDICAL)
6. 8F Hockey Stick (CORDIS) for aspiration post thrombectomy – pay attention to profunda and internal iliac veins
7. IVUS-Volcano (PHILIPS) to assess diameter and confirm need for a stent
8. 14 mm Atlas balloon (BARD) to 20 atm
9. Sinus Venous 14/150 stent (OPTIMED) – slow deployment; repeat balloon to same diameter and pressure
10. IVUS (PHILIPS) to confirm full stent expansion; followed by venography to confirm rapid flow

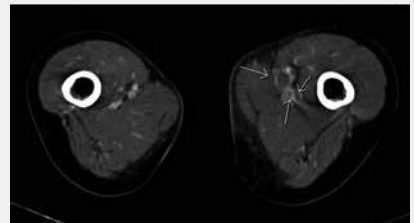


Fig. 3: note occlusive thrombus in left femoral vein with non-occlusive thrombus in left profunda femoris

TASC D calcified iliac occlusion right

Operators: A. Schmidt, M. Ulrich

Clinical data: Severe claudication right, walking-capacity 50-100 meters
Rutherford class 3, ABI right 0.46
COPD

Risk factors: Arterial hypertension, hyperlipidemia, strong smoker (50PY)

Procedural steps:

1. **Right femoral access**
 - 7F 25 cm Radiofocus Introducer (TERUMO)
 - 0.035" SupraCore guidewire 300 cm (ABBOTT)

Left brachial approach:

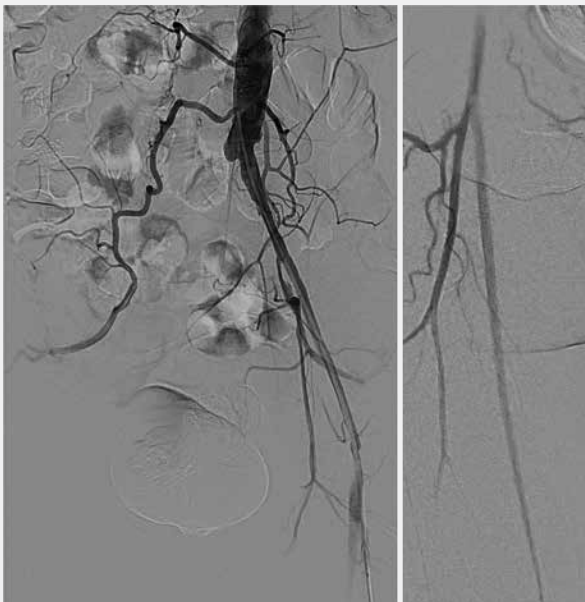 - 6F 90 cm Check-Flo Performer (COOK)
2. **Antegrade and retrograde guidewire passage**

brachial:

 - 5F Judkins Right diagnostic catheter 125 cm (CORDIS/CARDINAL HEALTH)

from femoral:

 - 5F Multipurpose diagnostic catheter 80 cm (CORDIS/CARDINAL HEALTH)
 - 0.035" stiff angled glidewire, 260 cm (TERUMO)
3. **Predilatation and stenting of the aorto-iliac bifurcation**
 - Ultraverse or Dorado balloon (BARD)
 - LifeStream covered stent 8/58 mm bilateral common iliac arteries in kissing-technique (BARD)
 - Covera Plus vascular covered stent for the external iliac artery (BARD)



Case 12 – ZUE 02: male, 24 years, (F-A)

Endovascular Y-reconstruction of chronic total occlusion of infrarenal inferior vena cava and iliofemoral veins

Operators: N. Kucher, D.-D. Do

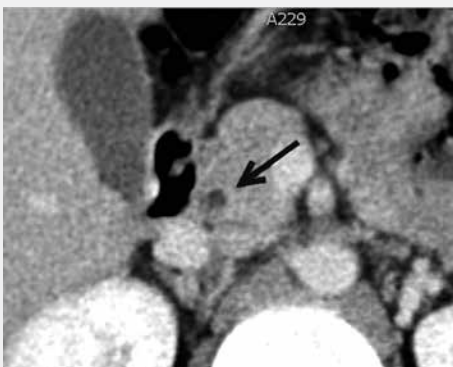Clinical data: Massive descending bilateral iliofemoral DVT in September 2018 including the infrarenal IVC diagnosed late and treated conservatively, ongoing shortness of breath, ongoing severe spinal and biliateral leg claudication, limited physical performance since childhood

Present state: Villata score: 6 points;
Spiroergometry: limited oxygen uptake during exercise due to impaired venous return

CT venography: Obtained 4 weeks after onset of symptoms:
- chronic total occlusion of perirenal inferior vena cava with descending DVT into both iliac and common femoral veins
- acygos collaterals

Duplex: Preserved leg inflow veins

- Procedural steps:**
1. General anaesthesia, ultrasound-guided access bilateral femoral veins (below occlusion) and possibly right jugular vein (10F)
 2. Passage of occlusion of vena cava and iliac veins stiff angled guidewire 0.035", Astato 0.018" CTO wire with 30 g tip load
 3. Lesion examination by selective venography two planes, intra-occlusion venography and provisional IVUS
 4. High pressure balloon angioplasty up to 20 mm in vena cava, up to 14 mm iliac veins
 5. Stenting of IVC with 20 mm Venovo stent (BARD) with high pressure postdilation up to 20 mm (Atlas Gold, BARD)
 6. Y-reconstruction of iliac confluens using Venovo (BARD) 14 mm kissing stents
 7. Kissing balloon postdilation of iliac confluens with 14 mm Atlas Gold balloons (BARD)
 8. Stent extension to both common femoral veins using Venovo 14 mm stents (BARD) with postdilation up to 14 mm high pressure
 9. Final venograms and assessment of peak flow velocity in both common femoral veins by Duplex sonography



Case 13 – GAL 03: male, 55 years

May-Thurner-Syndrome left

Operators: G. O'Sullivan, M. Mullin

Clinical data: 55 year old male presents with left lower limb swelling, pain and impending ulceration of the left lateral gaiter region December 2017.

Background History:

Antiphospholipid syndrome complicated by recurrent left sided DVT and PE

Aortic valve replacement complicated by subdural haematoma, requiring evacuation 2013

Recurrent subdural and subarachnoid haemorrhages due to lifelong anticoagulation

Important items: Antiphospholipid syndrome

DVT and PE. IVC filter in situ

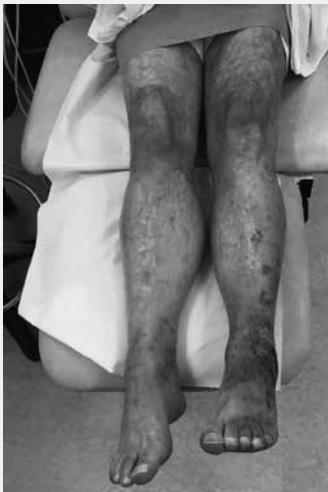Recurrent subdural and subarachnoid haemorrhages

CT venogram: IVC filter

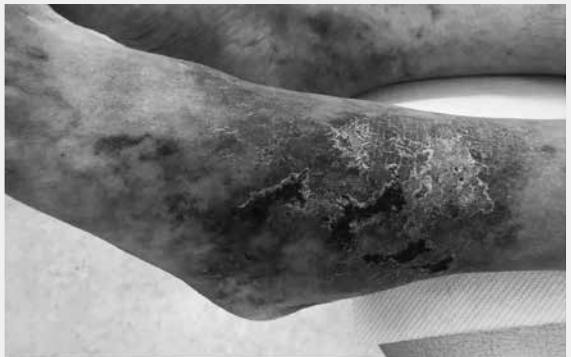Left sided May-Thurner syndrome

Bilateral lower limb varicose veins, including enlarged left greater saphenous vein.

Severe ulceration along LATERAL border left foot – normal ABPIs



Lower limb swelling with evidence of chronic venous hypertension, particularly the left lateral gaiter area.

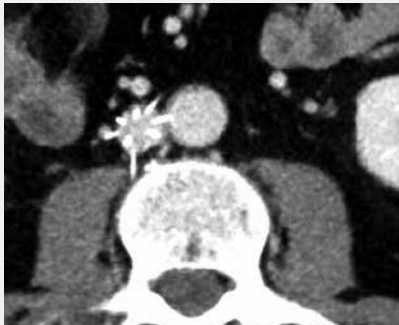


Left lateral malleolus area, showing impending ulceration. Peripheral pulses palpable; although this is typically arterial in position, venous can mimic most things.....

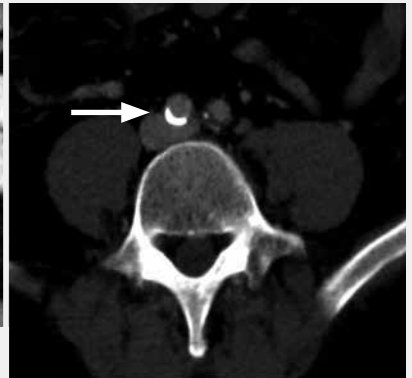Case 13 – GAL 03 (cont.)

Procedural steps:

1. **CT venogram. Supine. General anaesthetic. Urethral catheter**
2. **Right internal jugular vein puncture**
 - 5F microaccess kit (COOK); 10F 23 cm sheath
3. **Guidewire placement**
 - 260 cm Glidewire and 100 cm kumpe catheter to left common femoral vein.
 - 5000uIV Heparin.
4. **Biplanar venography**
 - (AP and LAO for left) and IVUS Volcano (PHILIPS) evaluation;
 - left iliac system under pressure;
 - but right may be abnormal also IVUS very helpful in this regard
5. **Balloon angioplasty from the common femoral veins to the renal IVC**
 - 14 - 16 mm angioplasty @ 18–20 atm (Atlas, BARD) of the common femoral and external iliac veins
 - 16 - 18 mm Atlas (BARD) @ 18–20 atm of the common iliac vein
6. **Stenting**
 - Abre (MEDTRONIC), Zilver Vena (COOK) or Venovo (BARD) 16/14mm diameter – uncertain of length as yet – stent from normal to normal
7. **Post stent balloon dilatation to nominal diameter stents**
8. **Repeat venography and IVUS**
9. **Post-op care**
 - Pneumatic boots until discharge and class II thigh high stockings 3/12
 - Anticoagulation for life as per haematology department
 - Follow-up colour doppler US day one post-op
 - Follow-up CT venogram 6/52
 - CTV at 6/52



Axial CT venogram. IVC filter in situ with numerous struts appearing beyond the IVC wall.



Axial CT venogram. Possible compression of the left common iliac vein (red arrow) by a calcified right common iliac artery (white arrow). Can this explain ALL of the left leg findings?

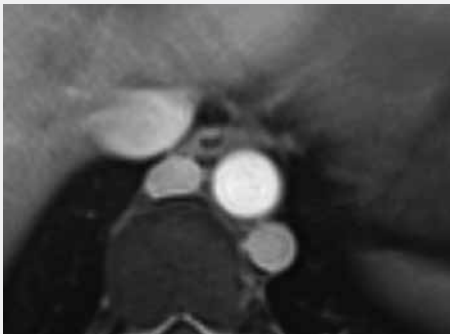Endovascular Y-reconstruction of chronic total occlusion of entire suprarenal and infrarenal inferior vena cava and iliac veins

Operators: N. Kucher, D.-D. Do

Clinical data: Limited physical performance
History of acute venous thrombosis right common iliac vein (2013)
Several catheterizations as newborn

Important items: MR-venography: atresia of entire inferior vena cava starting from the liver veins, bilateral common iliac vein occlusion, prominent collateral veins (vena azygos and lumbar veins)
Spiroergometry: limited oxygen uptake during exercise due to impaired venous return (60% of norm)
Villalta score: 9 points
Duplex: patent common femoral veins

- Procedural steps:**
1. General anaesthesia, Ultrasound-guided access: right and left common femoral veins and possibly right jugular veins (10F)
 2. Passage of occlusion of vena cava and iliac veins using stiff angled glidewire 0.035", Astatto 0.018" CTO wire with 30 g tip load, angled CXI 0.035" support catheter
 3. Lesion examination by selective venography two planes, intra-occlusion venography and provisional IVUS
 4. High pressure Balloon angioplasty up to 20 mm in vena cava, up to 14 mm iliac veins
 5. Stenting of IVC with two overlapping 20 mm Venovo (BARD) stents and high pressure postdilation up to 20 mm (Atlas Gold, BARD)
 6. Y-reconstruction of iliac confluens using Venovo 14 mm kissing stents (BARD)
 7. Kissing Balloon postdilation of iliac confluens with 14 mm Atlas Gold balloons (BARD)
 8. Possibly stent extensions to both external iliac veins using Venovo 14 mm stents (BARD) with postdilation up to 14 mm high pressure
 9. Final venograms and assessment of peak flow velocity in both common femoral veins by Duplex sonography



Case 15 – GAL 04: male, 66 years (H-G)

Failing dialysis graft

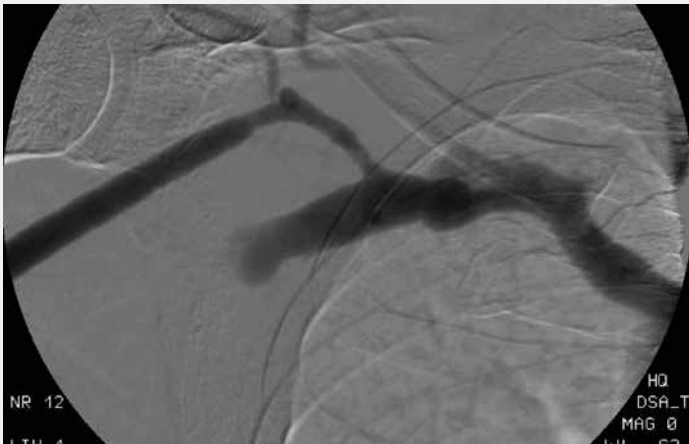
Operators: G. O'Sullivan, G. Rahmani

Clinical data: End stage renal disease. On maintenance haemodialysis through a right arm arterio-venous fistula- brachio-cephalic. High venous pressures with excessive bleeding post HD

Risk factors: Diabetes mellitus, haemodialysis

Procedural steps:

1. **Supine, local anaesthetic, right arm AV access towards heart**
 - 9F sheath
 - 3000u IV Heparin
2. **Initial venography to confirm lesion and measure appropriate diameter and length**
3. **Cross lesion under roadmap control; predilatation with 8 mm balloon**
4. **Lutonix (BARD) 8/40 drug eluting balloon**
5. **Covera (BARD) 8/60, 9/60, 10/60 stent graft**
6. **Completion venography**
7. **Purse string suture**
8. **Anti-platelet medications NSA 300mg stat and 75 mg/d x life**



Rapidly progressing right carotid artery disease in a 55-yrs old patient

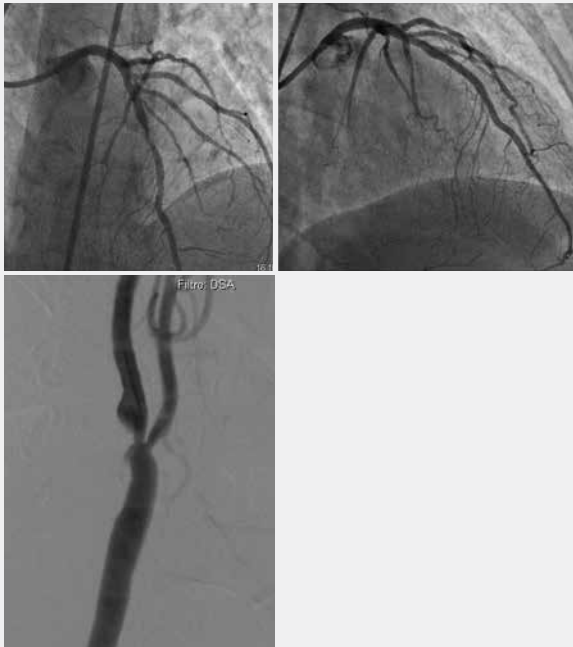Operators: F. Castriota, A. Micari

Clinical data: CVRFs: hypertension, hypercholesterolemia
Unstable angina treated with PCI to LAD (DES) in December 2018
(need for 12-month double antiplatelet therapy)

Duplex: Critical RICA stenosis (NASCET 80%) with evidence of a 'soft' fast-growing plaque (40% at Duplex scan performed in January 2018)

Procedural steps:

1. **Femoral access**
2. **Selective angiography**
3. **Cerebral protection**
 - MOMA 9F (MEDTRONIC) positioning
4. **Stenting**
 - Roadsaver (TERUMO) stent
5. **Postdilatation**
 - 5,0/20 mm balloon (BOSTON SCIENTIFIC)
6. **Femoral access haemostasis**



Case 17 – BLN 01: male, 62 years, (J-B)

High-grade, progressive RICA post radiation and open surgery for parotid tumor

Operators: R. Langhoff, A. Behne

Clinical data: Radiation and open surgery due to parotid cancer (years ago)
Renal insufficiency (last Creatinin level 2.3 mg/dl)

Duplex: High grade RICA, PSV 364 cm/sec, EDV >100 cm/sec, MDV 100 cm/sec

Risk factors: Ex-nicotine, art. hypertension

Present state: CTA and MRA not available due to impaired renal function

Procedural

1. Transfemoral access

steps:

- Short 8F sheath (TERUMO)

2. Placement of the guiding catheter

- 8F MP-shape guiding catheter sheath into the right CCA (Vista Brite IG, CORDIS)

3. Distal Protection

- Filter-wire EZ protection system (BOSTON SCIENTIFIC), alternatively Emboshield Nav 6 (ABBOTT VASCULAR)

4. Predilatation

- 3 x 20 mm Maverick balloon (BOSTON SCIENTIFIC)

5. Stenting

- Roadsaver 8 x 25 mm Micromesh-stent (TERUMO)

6. Postdilatation

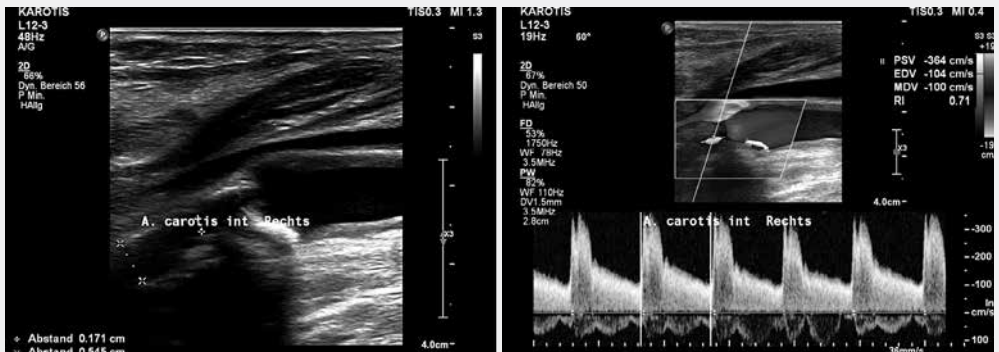
- 5 x 20 mm Maverick balloon (BOSTON SCIENTIFIC)

7. Removal of the stent delivery system and Filter Wire EZ system (BOSTON SCIENTIFIC)

8. Control angiography extra – and intracranial DSA

9. Access care

- Angioseal 8F (TERUMO)



Oblique hybrid stent placement for postthrombotic May Thurner Syndrome

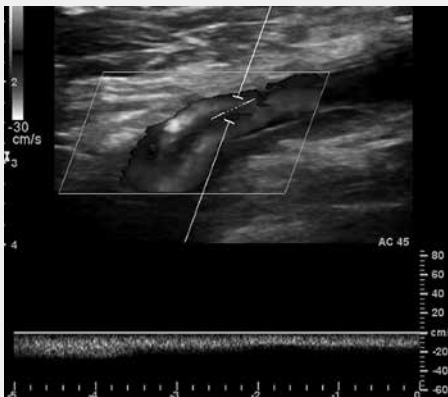
Operators: N. Kucher, D.-D. Do

Clinical data: History of acute iliac vein thrombosis (left) during complicated gemini-pregnancy in 23rd week of gestation treated with enoxaparin 1 mg/kg twice daily (in August 2018), caesarian section for twins in October 2018; currently breastfeeding and still treated with enoxaparin but severe venous claudication with leg swelling and venous claudication.

Duplex: Postthrombotic changes of common femoral veins, May Thurner anatomy with compressed left common iliac vein, preserved leg inflow veins

Ultrasound: Post-thrombotic changes left iliac and common femoral veins
Linear flow pattern left external iliac vein
Left common iliac vein compressed down to 2 mm (May-Thurner anatomy)

- Procedural steps:**
1. Ultrasound-assisted access left femoral vein (10F), analogosedation propofol, fentanyl
 2. Passage of iliac veins with stiff angled guidewire 0.035", Astato 0.018" CTO wire with 30 g tip load, 4F Berenstein catheter or angled CXI 0.035" support catheter
 3. Selective venography two planes, intra-occlusion venography, deep femoral vein imaging using balloon occlusion venography of common femoral vein and provisional IVUS
 4. Balloon angioplasty up to 14 mm (Atlas Gold, BARD)
 5. Left iliac vein stenting (Sinus obliquus 14 x 150 mm, OPTIMED)
 6. Provisional stent extension to common femoral vein (Sinus XL Flex 14 mm, OPTIMED)
 7. Postdilation high pressure up to 14 mm (Atlas Gold, BARD)
 8. Postdilation high pressure up to 14 mm (Atlas Gold, BARD)
 9. Final venograms and assessment of peak flow velocity in common femoral vein by Duplex sonography



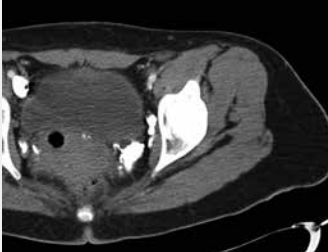
Case 19 – GAL 05: female, 34 years (L-E)

Chronic LLE swelling and venous claudication

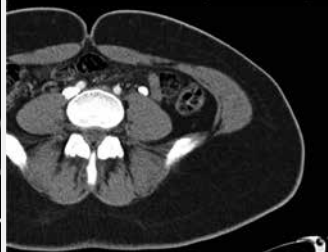Operators: G. O'Sullivan

Clinical data: Moderately swollen left leg; marked varicose veins; significant venous claudication

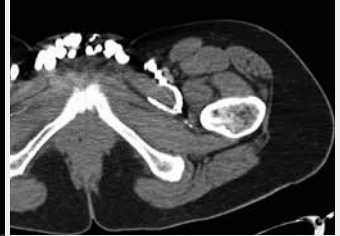Important items: Developed LLE DVT 2012 while on OCP. Repeat DVT LLE 2016.
No other risks. Non smoker. No longer on OCP. On life long anticoagulation.
CTV shows left ilio-femoral venous occlusion



DIRECT CTV note tiny L EIV, large R EIV collaterals+



Direct CTV, the L CIV is not visible, the enlarged vein anterior to the left psoas is the left ovarian.



Direct CTV through left foot injection shows obdurator hook sign and heavy cross pelvic collaterals

Procedural steps:

1. **Supine. GA. Urethral catheter.**
 - RIJF 10F sheath 30cm long. Left femoral venous puncture mid thigh 4F catheter.
 - 5000u IV Heparin
2. **Crossing the lesion**
 - 8F 55 cm Hockey stick to provide support.
 - Crossing catheter (CXI); choice of wires - angled glide;
 - stiff angled glide (both MERIT MEDICAL); Roadrunner (COOK)
3. **Confirm correct plane with oblique views, IVUS and venography.**
4. **Predilatation**
 - BARD Atlas 16 mm @ >20 atm L CIV; 14 mm @ >20 atm LEIV L CFV
5. **Stenting**
 - BARD Venovo or COOK Zilver Vena or MEDTRONIC ABRE of appropriate length
6. **Post dilatation to nominal diameter stents @ >20 atm**
7. **Completion venography and IVUS**
8. **Standard post op care**
 - Pneumatic boots, stockings - Class 2 thigh high; maintain full AC;
 - check CDUS day 1/30/18o

Asymptomatic very high grade LICA-Stenosis in a young vascular polytrauma

Operators: R. Langhoff, A. Behne

Clinical data: High grade bilateral ICA stenosis (left>right)
 Diabetic foot syndrom left
 Bilateral total SFA occlusions (PTA with DEB and Ultrascore 08/2018)
 Bilateral high grade CIA&EIA steosis (PTA and Stenting 08/2018)
 Coronary disease (2 vessel, symptomatic)
 High grade left renal stenosis
 Left Subclavian artery high grade stenosis

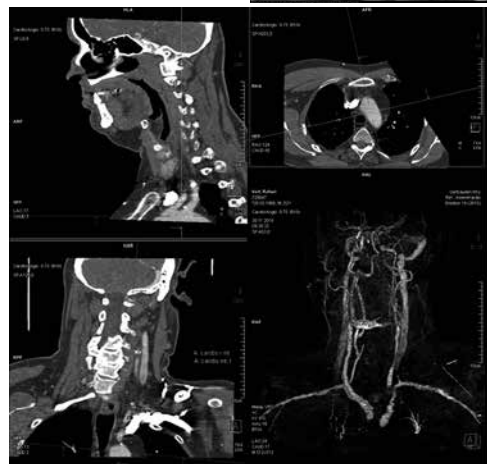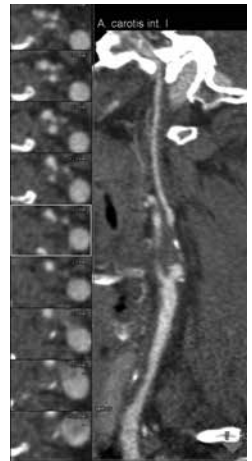
Risk factors: Smoker, diabetes mellitus, art. hypertension

CT: Aortic Arch Type 1, left ostial subtotal carotid artery stenosis

Duplex: High grade stenosis, not much calcium, straight vessel, soft plaques, high grade stenosis

Procedural steps:

1. **Transfemoral access**
 - Short 8F sheath (TERUMO)
2. **Sheath placement**
 - 8F MP-shape guiding catheter sheath into the left CCA (Vista Brite IG, CORDIS)
3. **Distal Protection**
 - Filter-wire EZ protection system (BOSTON SCIENTIFIC), alternatively Emboshield Nav 6 (ABBOTT VASCULAR)
4. **Predilatation**
 - 3 x 40 mm Maverick balloon (BOSTON SCIENTIFIC)
5. **Secondary protection/stenting/postdilatation**
 - Neuroguard IEP stent 9 mm (CONTEGO MEDICAL) filter, Nitinol stent and postdilatation balloon in one system
6. **Removal of the stent delivery system and Filter Wire EZ system (BOSTON SCIENTIFIC)**
7. **Control angiography extra – and intracranial DSA**
8. **Access care**
 - Angioseal 8F (TERUMO)



Case 21 – BG 02: male, 64 years (D-V)

Symptomatic left carotid artery disease in a patient with coronary artery disease

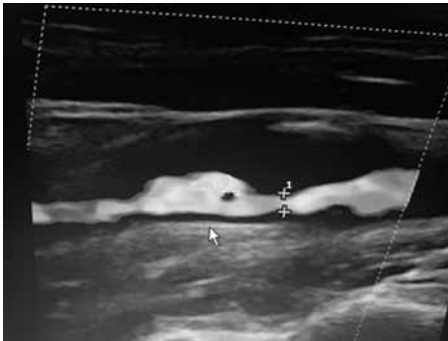
Operators: F. Castriota, A. Micari

Clinical data: Stable angina during the last 12 months, 1 hospital admission for TIA (transient dysarthria) 1 month ago

Risk factors: Hypertension, hypercholesterolemia

Duplex: Critical LICA stenosis with evidence of a 'soft' plaque

- Procedural steps:**
1. **Femoral access**
 2. **Selective angiography**
 3. **Cerebral protection**
 - MOMA 9F (MEDTRONIC) positioning
 4. **Stenting**
 - C-Guard (INSPIRE MD)
 5. **Postdilatation**
 - 5,0/20 mm balloon (BOSTON SCIENTIFIC)
 6. **Femoral access haemostasis**



Case 22 – BLN 03: female, 85 years (G-I)

CTO Left popliteal artery (11 cm length)

Operators: R. Langhoff, G. Hardung

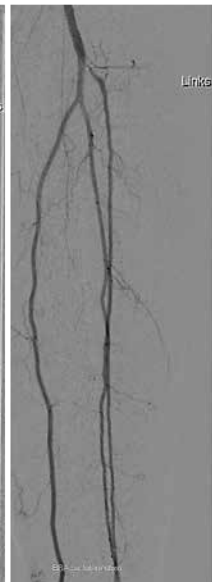
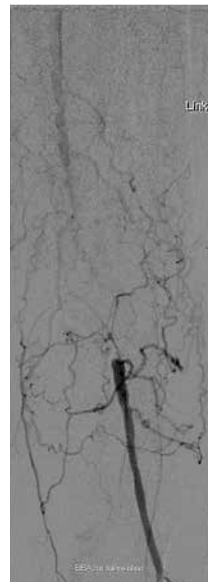
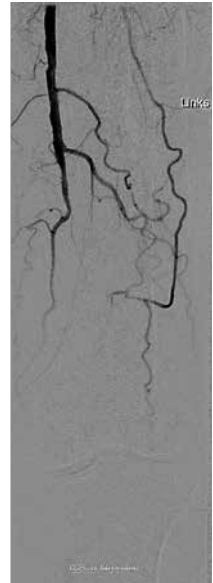
Clinical data: Recanalisation of the right popliteal artery CTO in 11/2018, PTA with Sequent Please OTW and 4 Multiloc 5 x 13 mm stents. Deep vein thrombosis in 02/2018 with DOAK for 6 months

Present state: ABI left 0.7, walking distance <50 mm, calf claudication, Duplex and Angio showed popliteal segment I CTO

Risk factors: Smoking, art. hypertension

Procedural steps:

1. **Cross-over access**
 - 6F Fortress 45 cm sheath (BIOTRONIK) right to left
2. **Catheter for lesion crossing**
 - Navicross 0.035" support catheter 90 cm (TERUMO)
3. **Guidewire for lesion crossing**
 - Angled stiff guidewire, 260 cm (TERUMO)
4. **Lesion crossing**
5. **Backup retrograde access**
 - 0.018" approach, sheathless with CXI 0.018" support catheter (COOK)
6. **Predilation**
 - 3 x 120 mm Passeo 35 balloon (BIOTRONIK)
7. **PTA**
 - 5 x 120 mm Sequent Please OTW DEB (B. BRAUN)
8. **Spot Stenting**
 - Multi-Loc 5 x 13 mm if needed (B. BRAUN)
9. **Postdilation if stent was necessary**
 - 5 mm POBA (BIOTRONIK)
10. **Sheath removal and vessel closure**



Case 23 – LEI 07: male, 61 years (R-F)

Long calcified SFA-occlusion left

Operators: S. Bräunlich, A. Schmidt

Clinical data: Severe claudication left calf, walking capacity 50 meters, ABI left 0.62
Femoro-popliteal bypass right 2012, thrombendatherectomy left groin 01/2019
CEA left 11/2012 and right 12/16, CAD, AMI 1997

Risk factors: Art. hypertension, diabetes mellitus type 2, nicotine abuse (80PY), hyperlipidemia

Procedural steps:

1. Right groin and cross-over access

- IMA-diagnostic 5F catheter (CORDIS/CARDINAL HEALTH)
- 0.035" angled soft Radiofocus guidewire, 190 cm (TERUMO)
- 0.035" SupraCore guidewire, 190 cm (ABBOTT)
- 7F Balkin Up&Over sheath, 40 cm (COOK)

2. Antegrade guidewire-passage

In case of failure from antegrade:

Retrograde GW-passage via proximal ATA

- 21 Gauge 9cm needle (B.Braun)
- 0.018" V-18 Control GW, 300cm (BOSTON SCIENTIFIC)
- 0.018" CXC Support-Catheter, 90cm (COOK)

3. In case of failure to pass the guidewire

- retrograde approach via distal SFA or
GoBack™ Crossing Catheter (Upstream Peripheral) from antegrade

4. Tumescant anesthesia of the SFA

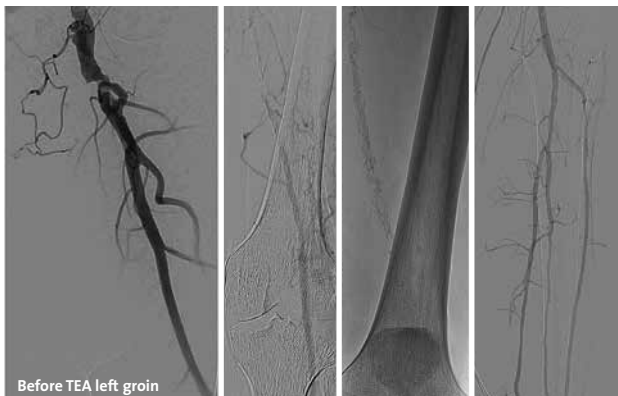
- Bullfrog-Device (MERCATOR)

5. PTA/vessel preparation

- Sterling 5/100 mm balloon (BOSTON SCIENTIFIC)
- Conquest High pressure balloon on indication (BARD)

6. Differential stenting

- Eluvia DES in case of minor recoil (BOSTON SCIENTIFIC)
- Supera Interwoven Nitinol-Stent in case of severe recoil (ABBOTT)



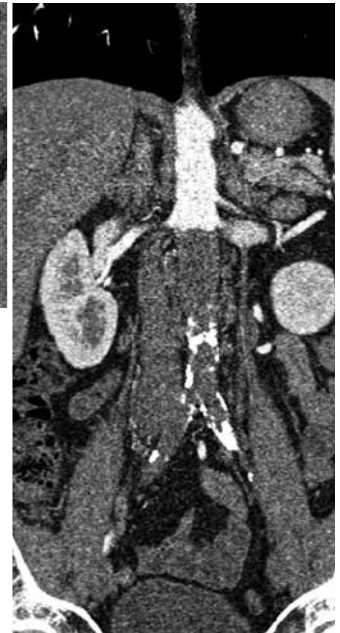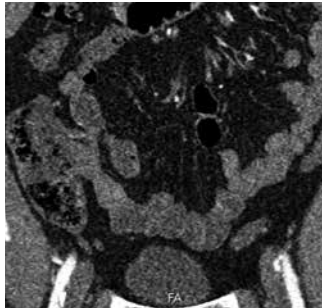
Case 24 – LEI 08: male, 46 years (A-G)

Chronic occlusion of the abdominal aorta and aortic bifurcation, Leriche-Syndrome

Operators: A. Schmidt, M. Ulrich

Clinical data: PAOD Rutherford 3 bilateral, ABI bilateral 0.5
Absolute walking-capacity 100 meters, weakness both thighs/calves

Risk factors: Art. hypertension, nicotine abuse (30PY)



Procedural steps:

1. **Transbrachial approach**
 - 6F 90 cm Check-Flo performer sheath (COOK)
 - 5F 125 cm diagnostic Judkins Right catheter (CORDIS/CARDINAL HEALTH)
 - SupraCore 300 cm 0.035" guidewire (ABBOTT)
2. **Passage of the occlusions**
 - Stiff angled 0,035" guidewire, 260 cm (TERUMO)
 - Together with 5F-125 cm Judkins Right catheter
3. **Bilateral groin access**
 - 7F 10 cm Radiofocus sheath (TERUMO)
 - Snaring of the antegrade guidewire from above into the groin-sheath or
 - Into 6F-Judkins-Right guiding catheter (CORDIS) inserted from below
4. **PTA/thrombectomy via the groin access bilateral**
 - Rotarex 10F thrombectomy (STRAUB MEDICAL)
 - SupraCore 300 cm 0,035" guidewire (ABBOTT)
 - Admiral balloon 6.0/120 mm bilateral (MEDTRONIC)
5. **Implantation of covered stents**
 - VBX covered stents for both renal arteries (GORE)
 - VBX covered stents bilateral in kissing technique (GORE)

Case 25 – NY 03: male, 57 years (P-P)

Right common and external iliac artery occlusion

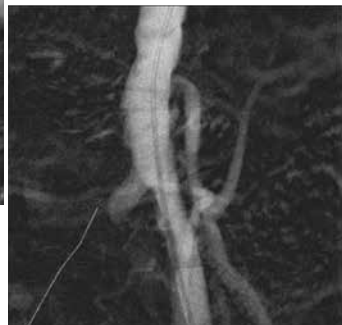
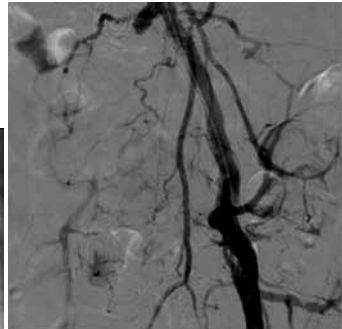
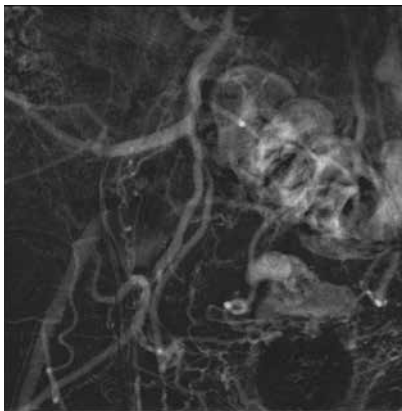
Operators: P. Krishnan, V. Kapur

Clinical data: Progressively worsening claudication of right lower extremity x 1 year.
Failed exercise therapy and unable to tolerate Cilostazol.
Unsuccessful attempt of right Iliac angioplasty at outside facility.
ABI 0.56/0.92.

Risk factors: Type 2 DM, HTN, dyslipidemia, CKD

Procedural steps:

1. **Right radial artery access**
 - 6-7 Slender sheath (TERUMO)
2. **Right CFA access**
 - Micropuncture sheath (COOK) under Road Map guidance
3. **Antegrade lesion crossing**
 - 0.014" wire platform
 - Wire escalation to 0.018" to 0.035" in sequential fashion
 - If fails will attempt retrograde
4. **Wire externalization**
5. **Predilatation**
 - 6.0 x 60 mm Dorado balloon (BARD)
6. **Stenting**
 - Viabhan VBX ste nt (GORE)



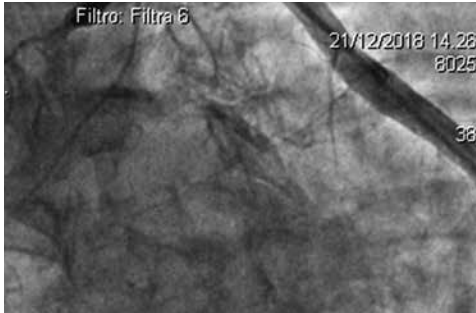Case 26 – BG 03: female, 78 years (N-5)

Symptomatic left subclavian artery stenosis

Operators: A. Micari, F. Castriota

Present state: During the last 3 months she referred effort left arm pain (while doing homework). One week ago 1 episode of marked dizziness while climbing stairs. Duplex showed critical left subclavian artery stenosis (then confirmed by angio)

Risk factors: Hypertension, hypercholesterolemia
Known history of CAD (previous PCI to LM-LAD and RCA)



Procedural steps:

1. **Femoral access**
2. **Left radial access**
3. **Lesion crossing**
 - 0.018" wire
4. **Lesion predilation**
 - cutting balloon (Wolverine, BOSTON SCIENTIFIC) and drug-coated balloon (Ranger, BOSTON SCIENTIFIC)
5. **Stenting**
 - Innova self-expanding stent (BOSTON SCIENTIFIC)
6. **Postdilatation**

Case 27 – LEI 09: female, 56 years (L-K)

Restenosis of the left common carotid artery after TEA

Operators: A. Schmidt, S. Bräunlich

Clinical data: Asymptomatic highgrade stenosis of the the common carotid artery left, dizziness
M. Hodgkin 1984 with cervical radiation
CEA right 09/16 and CEA of left common carotid artery 05/17

Risk factors: Art. hypertension, hyperlipidemia, former smoker

Duplex: 4.8 m/sec. Left distal common carotid artery

Procedural

1. Right groin access

steps:

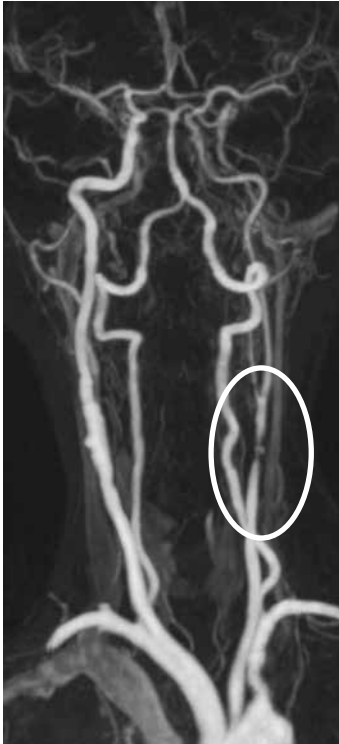- 5F Judkins Right diagnostic catheter (CORDIS/CARDINAL HEALTH)
- 0.015" SupraCore guidewire (ABBOTT)
- 7F 90cm Check Flo Performer sheath (COOK)

2. Cerebral protection

- Filter-wire EZ (BOSTON SCIENTIFIC)

3. Predilatation and Stenting

- 3.5/20 mm MiniTrek Monorail balloon (ABBOTT)
- 8/30 mm CGuard stent (InspireMD)



Case 28 – BG 03: male, 66 years (CP-B)

For case information
please download the LINC 2019 App
or visit the LINC 2019 website.

Case 29 – BLN 04: male, 62 years, (J-B)

Diabetic foot syndrome with CTO of tibioperoneal trunc and distal occlusion of the ATP

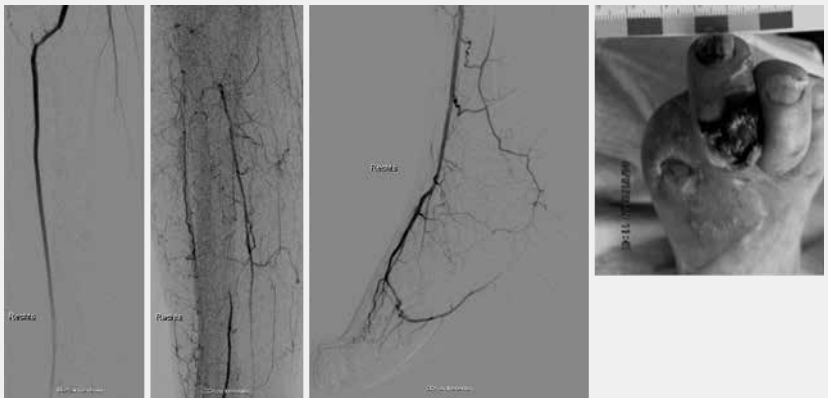
Operators: R. Langhoff, M. Boral

Clinical data: Gangrene Dig. ped. II right, persistend occlusion of right tibioperoneal trunc
Diabetes mellitus
Minor amputation of right foot Dig ped I ex-articulation of end-phalanx
PTA and Supera stenting right SFA & popliteal artery 01/2019
Impaired renal function
TEA and Patch bilateral common femoral artery (2015)

Risk factors: Hyperlipidemia (Lipidapheresis since 2016), art. hypertension
CHD (post-MI), recanalisation of inflow was done by cross-over approach,
wound is only slowly improving

Procedural steps:

- 1. Antegrade access**
 - Destination 5F sheath (45 cm) right CFA (TERUMO)
- 2. Recanalisation**
 - supported by CXI Supportcatheter 0.018" (COOK)
and Advantage Glidewire 0.018" (TERUMO)
- 3. PTA**
 - 2 x 40 mm ballon Passeo 18 (BIOTRONIK)
- 4. Recanalisation of the tibioperoneal trunc & distal ATP to the pedal arch and PTA**
- 5. Stenting of the tibioperoneal trunc**
 - 3.0 x 31 mm Cre8 BTK dedicated DES (ALVIMEDICA)
- 6. BACK-UP: transpedal-loop recanalisation of the ATP via the ATA**
 - 0.014" Corsair Microcatheter (ASAHI) and 0.014" Advantage Wire (TERUMO)



LEIPZIG
INTERVENTIONAL
COURSE
2019

L I N C

Wednesday,
January 23, 2019

Wednesday

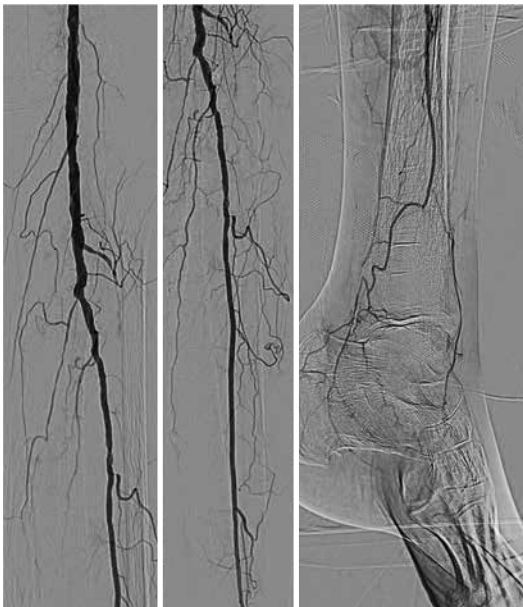
Case 30 – LEI 10: female, 79 years (G-H)

CLI with CTO BTK left

Operators: S. Bräunlich, A. Schmidt

Clinical data: Critical limb ischemia both lower legs with chronic ulcerations, Rutherford class 5
 ABI left 0.34, ABI right 0.45
 Recanalization right peroneal artery 01/07/2018
 PTA SFA/popliteal artery left and PTA anterior tibial right 11/2018
 Amputation forefoot left
 Amputation D1 right

Risk factors: Diabetes mellitus type 2 with diabetic neuropathy, arterial hypertension, chronic renal impairment



Procedural steps:

1. **Antegrade approach left groin**
 - 6F 55 cm sheath (COOK)
2. **Guidewire-passage anterior/posterior tibial**
 - 0.014" Command (ABBOTT)
 - 0.014" PT2 Guidewire 300 cm (BOSTON SCIENTIFIC)
 - In case of failure: retrograde approach
3. **PTA**
 - Vessel preparation – scoring balloon (VascuTrak, BARD)
 - Lutonix BTK DCB (BARD)
4. **In case of dissections after DCB, provisional placement of nitinol "tacks"**
 - Tack Endovascular System (INTACT VASCULAR)

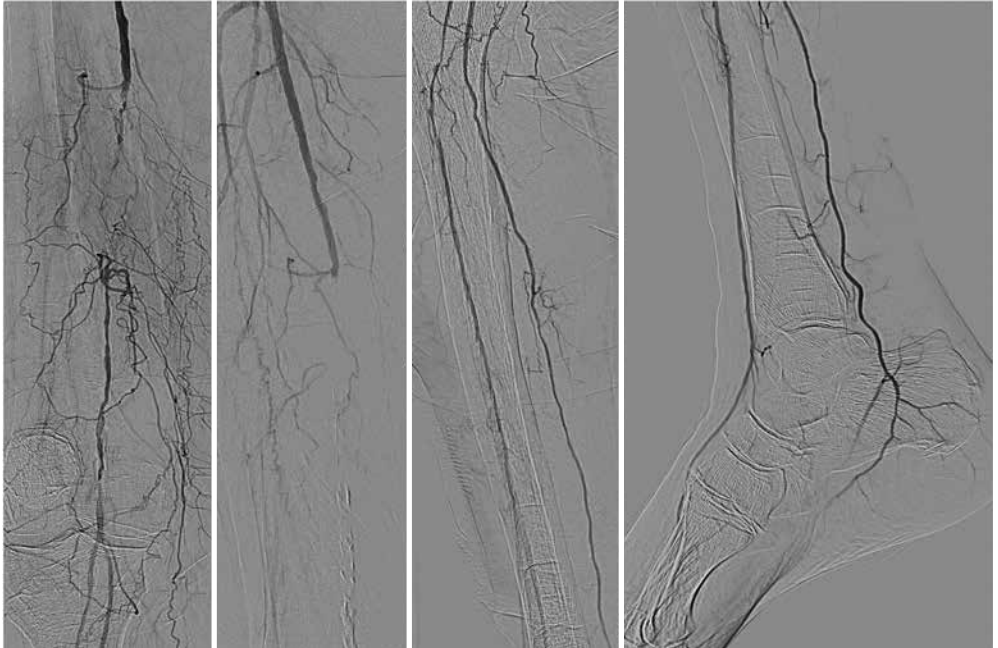
Case 31 – LEI 11: female, 76 years (R-5)

Calcified distal SFA-occlusion, CLI

Operators: M. Ulrich, S. Bräunlich

Clinical data: PAOD Rutherford class 5, forefoot ulcerations, restpain and severe claudication right, ABI 0.4
Aortic valve replacement 2013, NSTEMI 09/2018, PTCA 09/18
Renal impairment grade 4

Risk factors: Arterial hypertension, hyperlipidemia, diabetes mellitus type 2



Procedural steps:

1. **Left femoral retrograde and cross-over approach**
 - 7F 55 cm Check-Flo Performer, Raab Modification (COOK)
2. **Guidewire passage and filter placement**
 - 0.018" V-18 Control guidewire, 300 cm (BOSTON SCIENTIFIC)
 - 5 mm Spider filter (MEDTRONIC)
3. **Atherectomy**
 - 2.4/3.4 mm JetStream atherectomy device (BOSTON SCIENTIFIC)
4. **PTA with DCBs and stenting on indication**
 - Ranger DCB balloon (BOSTON SCIENTIFIC)
 - Eluvia drug-eluting stent (BOSTON SCIENTIFIC)

Case 32 – MUN 01: male, 69 years (A-S)

BTK intervention

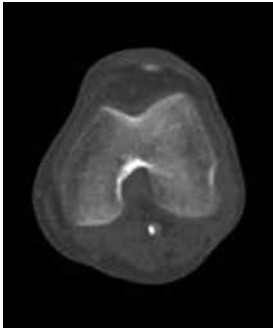
Orbital atherectomy system (360° Stealth, CSI)

Operators: A. Schwindt, K. Donas

Clinical data: CAD, PTCA 2015, art. hypertension, PAD, COPD, calf claudication on the left side after 50 m with progress

Present state: Subtotal occlusion with calcification of the popliteal artery

- Procedural steps:**
1. Percutaneous approach from the contralateral femoral artery
 2. Use of 6F 45 cm long sheath with placement in the external iliac artery
 3. Recanalisation of the subtotal occlusion of the popliteal artery
 4. Use of the orbital atherectomy system (360°, Stealth) CSI as lithoplasty option of the severe calcified lesion to prepare the vessel
 5. Use of a DCB balloon
 6. Closure of the groin with Angioseal 6F system



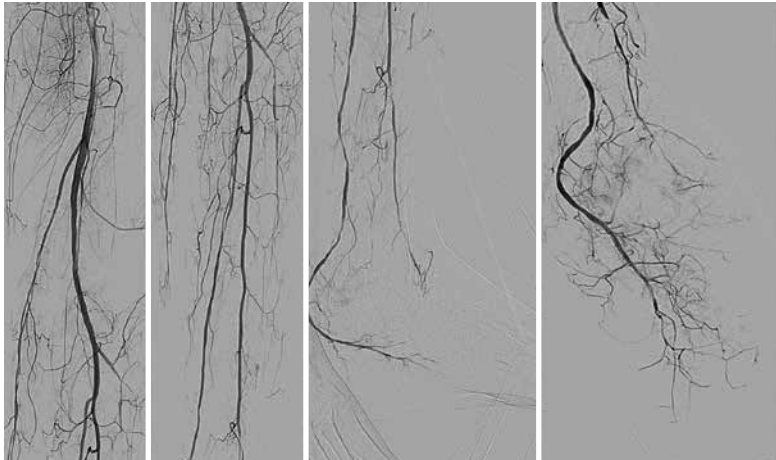
Case 33 – LEI 12: male, 68 years (J-K)

CLI, deep vein arterialization of a "desert foot" left

Operators: A. Schmidt, S. Kum, D. Branzan

Clinical data: PAOD Rutherford 5, non-healing forefoot gangrene, mediasclerosis, ABI > 1.4
 PTA left peroneal artery 07/18 and left TPA 08/18
 Terminal kidney disease
 Paroxysmal atrial fibrillation, pacemaker 12/17

Risk factors: Arterial hypertension, hyperlipdemia, dialysis



Procedural steps:

1. **Left groin antegrade access**
 - 7F 55 cm Flexor Check-Flo sheath, Raabe Modification (COOK)
 - Left distal venous tibial retrograde access
 - 5F sheath Introducer 2® (TERUMO)
 - Arteriography and phlebography to define the optimal level for arterio-venous crossing
2. **Crossing from artery to vein**
 - LimFlow Arterial Catheter 7F (LIMFLOW)
 - LimFlow Venous Catheter 5F (LIMFLOW)
 - LimFlow Ultrasound System (LIMFLOW)
 - PT2 0.014" Guidewire to pass from artery into vein (BOSTON SCIENTIFIC)
 - Predilatation with MiniTrek 3.5/20 mm OTW Coronary Balloon (ABBOTT)
3. **Guidewire passage through vein and vein preparation**
 - PT2 0.014" guidewire (BOSTON SCIENTIFIC) or
 - Command 18 guidewire (ABBOTT)
 - Push Valvulotome 4F (LIMFLOW)
 - 4.0/120 mm Pacific balloon (MEDTRONIC)
4. **Implantation of covered stentgrafts**
 - LimFlow Extension stentgrafts 7F 5.5 mm x 150 mm (LIMFLOW) for vein coverage
 - LimFlow Crossing Stentgraft 7F 3.5 x 60 mm (LIMFLOW) for connection artery to vein

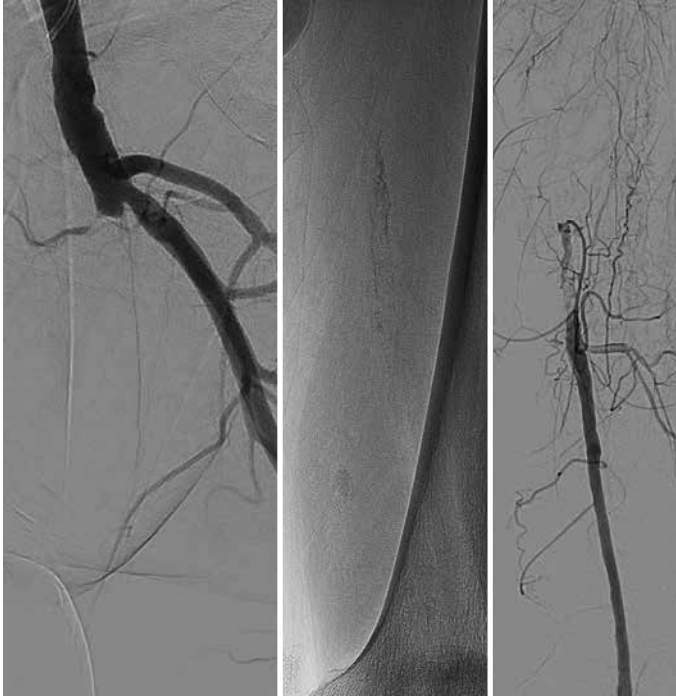Case 34 – LEI 13: male, 65 years (G-Z)

Occlusion of the left SFA

Operators: M. Ulrich, A. Fischer

Clinical data: PAOD Rutherford 3, walking capacity of 40 m, claudication left calf
ABI left 0.6

Risk factors: Arterial hypertension, hyperlipidemia, strong smoker (50PY)



Procedural steps:

1. Right groin cross-over approach

- Judkins Right 5F diagnostic catheter (CORDIS/CARDINAL HEALTH)
- 0,035" SupraCore guidewire 30 cm (ABBOTT)
- 6F-55 cm Balkin Up&Over sheath (COOK)

2. Guidewire passage

- 0.035" stiff, angled glidewire, 260 cm (TERUMO)
 - 0.035" Seeker support catheter, 135 cm (BARD)
- In-case of inability to reenter distal:
- either retrograde approach via distal SFA or
GoBack Crossing Catheter (UPSTREAM PERIPHERAL)

3. Angioplasty

- ULTRASCORE Balloon 5,0/100 mm (BARD)
- Lutonix GEOALIGN marking system DCB 6.0/120 mm (BARD)

Case 35 – COL 01: 71 years (W-M)

Severe, asymptomatic left internal carotid artery stenosis

Operators: M. A. Jolly, G. Ansel

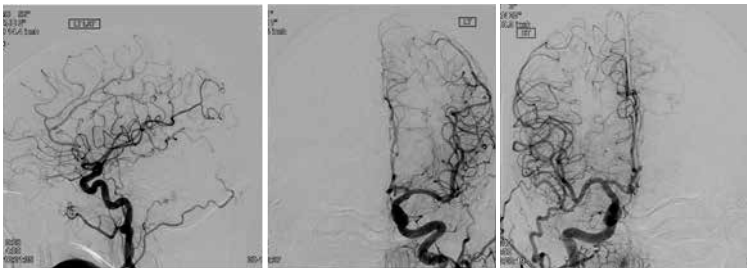
Clinical data: Yearly carotid artery surveillance given diffuse vascular disease. Asymptomatic patient with progressive LICA disease over past year. On optimal medical therapy (ASA, clopidogrel, atorvastatin 80 mg, losartan 100 mg). Pt unwilling to undergo carotid surgery.

Risk factors: CAD s/p 4vCABG 2000, prior subsequent PCI, HTN, HLD, ischemic cardiomyopathy (EF 40%), stable angina

Present state: Asymptomatic, denies TIA/CVA/amarosis fugax

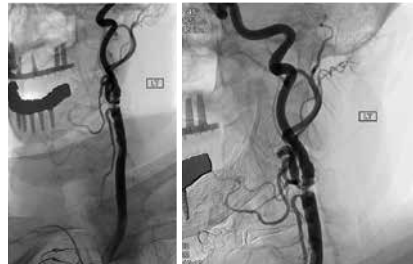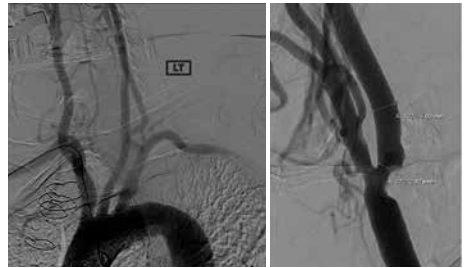
Duplex: Carotid duplex Nov 2018 – RICA 157/21 cm/s ratio 2.0, LICA 290/104, ratio 5.2; CT neck: 70-80% LICA stenosis, no significant LCCA stenosis

Angiogram: Carotid angiogram: 80% LICA bifurcation stenosis by NASCET



Procedural steps:

1. **Micropuncture femoral artery access**
2. **Sheath placement**
 - 6F 90 cm braided sheath delivery into LCCA
3. **Distal embolic protection**
 - Nav6 Emboshield wire (ABBOTT)
4. **Stenting**
 - Xact 10-8 x 40 mm (ABBOTT)
5. **Predilatation**
 - 4x20 mm NC balloon (ABBOTT)
4. **Postdilatation**
 - 5 x 30 mm NC balloon (ABBOTT) (if necessary)



Case 36 – COL 02: male, 73 years (R-B)

Severe asymptomatic right internal carotid artery stenosis

Operators: G. Ansel

Clinical data: Presented in January, 2019, for evaluation of progressive right internal carotid artery stenosis with small penetrating ulcer/pseudoaneurysm of the lateral wall and stable moderate disease of the left carotid bulb. Had recent coronary CTA with high level readings but stress echo negative for ischemia.

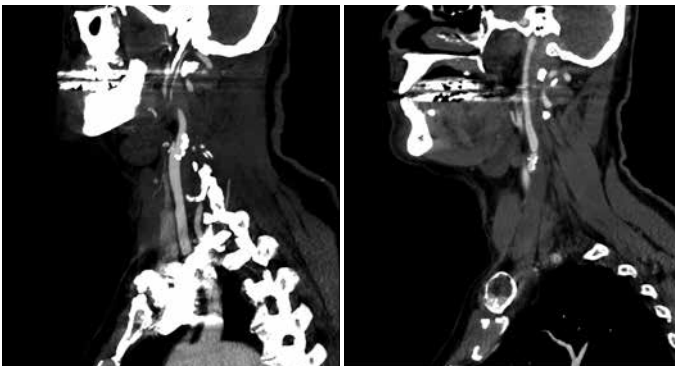
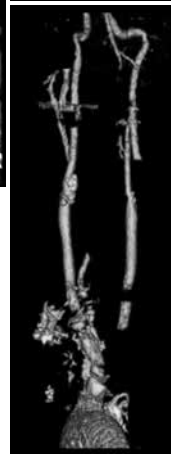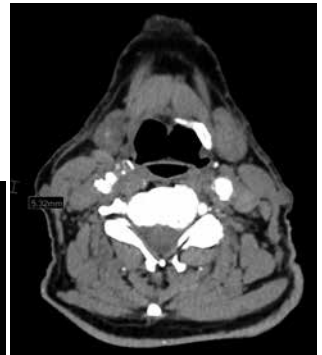
Risk factors: CAD, PAD, tobacco abuse, HLD

Present state: No CVA/TIA-like symptoms or angina

Duplex: Carotid Duplex 11/2018: RICA max PSV 319 cm/s, RICA/CCA ratio= 3.45; LICA max PSV 121 cm/s, LICA/CCA ratio= 1.01

CTA: CTA head/neck 12/18: Severe focal stenosis (90% stenosis) at origin of right internal carotid artery, with an associated 5 x 5 x 15 mm atherosclerotic penetrating ulcer or pseudoaneurysm at the lateral aspect of the origin of the right internal carotid artery. NO flow limiting stenosis of left carotid system.

- Procedural steps:**
1. Femoral access
 2. Shuttle sheath (COOK)
 3. Mo.ma proximal protection device (MEDTRONIC)
 4. Xact Stent (ABBOTT VASCULAR)



Case 37 – LEI 14: female, 76 years (U-C)

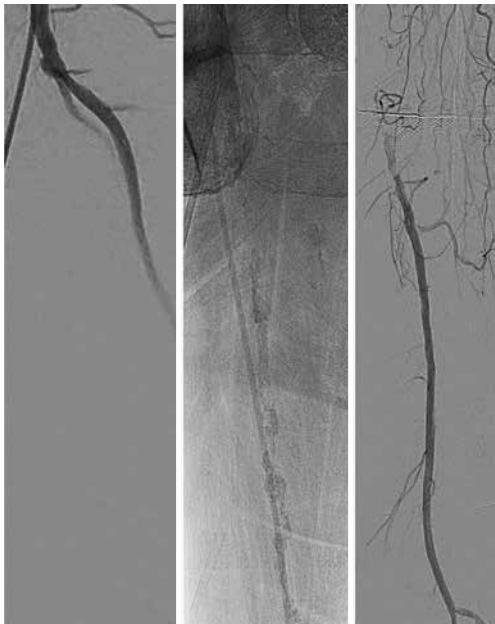SFA-occlusion left, treatment according to BEST-SFA study randomization

Operators: A. Schmidt, M. Ulrich

Clinical data: Severe claudication left calf, ABI 0.65; walking-capacity 100 meters
 Rutherford class 3
 PTA / Stenting right SFA
 TEA right CFA 2017, PTA/stent right SFA 2017
 CAD, CABG 1988, PTCA 2012

Risk factors: Arterial hypertension, heavy smoker

Angiography: Obtained during PTA right SFA: Calcified SFA-CTO left



Procedural steps:

1. **Right retrograde and cross-over approach**
 - 7F 40 cm Up&Over sheath (COOK)
2. **Guidewire passage from antegrade**
 - 0.018" Command 18 guidewire, 300 cm (ABBOTT)
 - GoBack Crossing catheter (UPSTREAM PERIPHERAL) in case of failure to pass with a GW
3. **After guidewire passage**
 - randomization to either
 - 'best' stenting strategy Eluvia DES (BOSTON SCIENTIFIC) and/or Supera (ABBOTT) or
 - 'best' DCB treatment (potentially including atherecomty) Inpact (MEDTRONIC)

Case 38 – COL 03: male, 58 years

Instent restenosis case

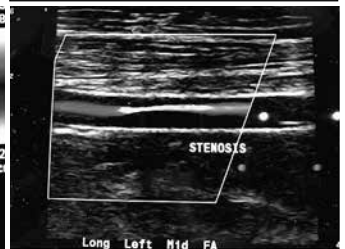
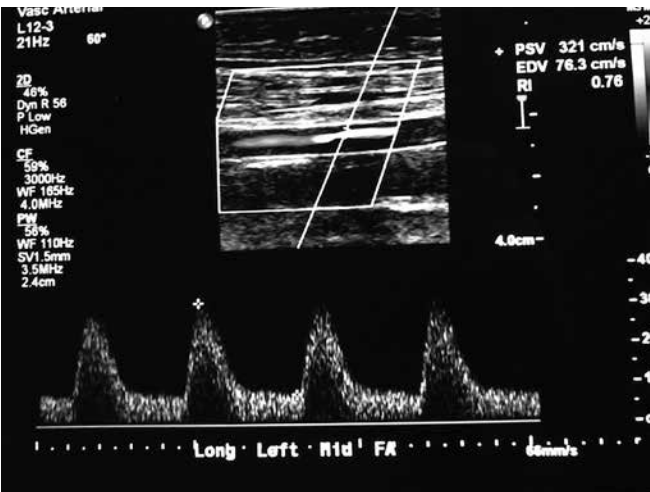
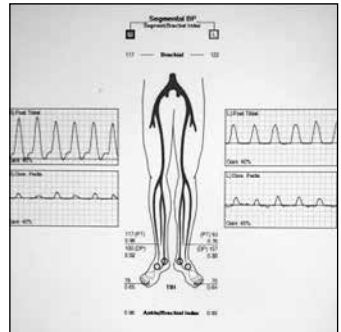
Operators: M. Silver, M. Jolly, C. Huff, G. Ansel

Clinical data: Pt with 4 year history of PAD, s/p multiple interventions of the iliac, femoropopliteal and tibial vessels for claudication and previous critical limb Ischemia. Originally treated multilevel for left foot ulceration in 2015, restenosis of iliacs treated with stent grafts, SFA occlusion attempted to be treated with cilostazol but no effect at 3 months. Now s/p Super stent in 2015 that occluded, treated with DCB and proximal DES extension in 2017. Now with recurrent RC II claudication and duplex scan with restenosis
ABI R: .96 and L: .88

Risk factors: DM II, CAD, HTN, hyperlipidemia, past smoker

Duplex: Peak velocity of 343 within the stent

- Procedural steps:**
1. Contralateral femoral access
 2. Placement of 7F or 8F braided sheath
 3. Excimer Laser debulking
 4. High pressure PTA
 5. If good result DCB, if poor result consider DES
 6. Suture based sheath removal



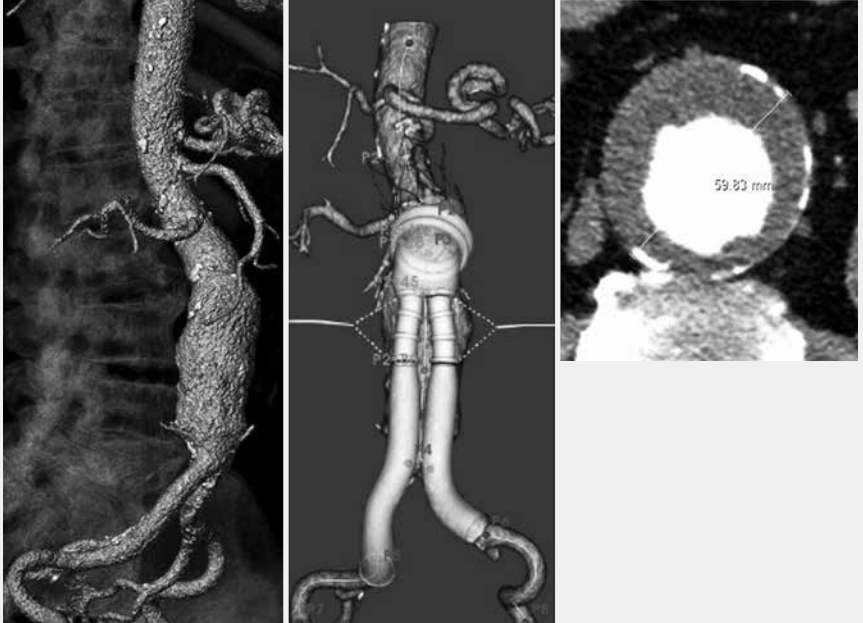Case 40 – LEI 15: male, 77 years (G-G)

Infrarenal AAA

Operators: A. Schmidt, D. Branzan

Clinical data: Asymptomatic infrarenal AAA, diameter max. 58 mm
Coiling of lumbar arteries 12/2018

Risk factors: Art. hypertension, chronic renal impairment, hyperlipidemia



Procedural steps:

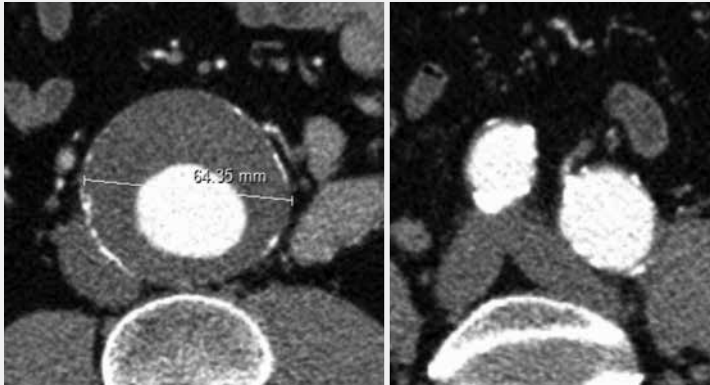
- 1. Bifemoral percutaneous approach**
 - in local anaesthesia
 - Preclosing with 2 Proglide closure devices both sides (ABBOTT)
- 2. Guidewire positioning**
 - Lunderquist GW 180 cm (COOK)
- 3. Implantation of a bifurcational stentgraft**
 - Ovation Stentgraft (ENDOLOGIX)
 - Cannulation of the contralateral limb:
 - 5F Amplatz Left diagnostic catheter (CORDIS/CARDINAL HEALTH)
 - 0.035" soft angled short Radiofocus glidewire (TERUMO)
- 4. PTA**
 - Proximal seal: Reliant balloon (MEDTRONIC)
 - Graft-bifurcation: 12/40 mm Admiral balloon (MEDTRONIC)

Aortoiliac aneurysm – EVAR and iliac branch device

Operators: A. Schmidt, D. Branzan

Clinical data: Asymptomatic infrarenal AAA (max. diameter 64 mm) and aneurysm of the left common iliac artery (max. diameter 39 mm)
Coiling of segmental arteries and IMA 11/2018
Renal impairment G2

Risk factors: Arterial hypertension, hyperlipidemia, current smoker



Procedural steps:

1. **Bifemoral percutaneous approach**
 - Preloading with 2 Proglide systems/side (ABBOTT)
 - Lunderquist GW 260 cm (COOK)
2. **Implantation of the iliac Side-Branch-Device**
 - ZBIS 12-45-41 via left side (COOK)
 - 12F 45 cm sheath Flexor Check-Flo Introducer, Ansel Modification 1 via right groin (COOK)
 - Pullthrough guidewire: 0.035" glidewire 260 cm (TERUMO)
 - Snare for pullthrough-GW: Amplatzer Goose Neck Snare Kit 10 mm (MEDTRONIC)
3. **Implantation of bridging-stents into the hypogastric artery left**
 - 8.0/57 mm BeGraft Peripheral covered stent (BENTLEY)
4. **Implantation of a bifurcational stentgraft**
 - Zenith Alpha (COOK)
 - Cannulation of the contralateral limb:
 - 5F Amplatzer Left Diagnostic catheter (CORDIS - CARDINAL HEALTH)
 - 0.018" Control guidewire, 300 cm (BOSTON SCIENTIFIC)
5. **PTA of the graft**
 - Coda balloon catheter (COOK)

Case 42 – MUN 03: male, 80 years (F-E)

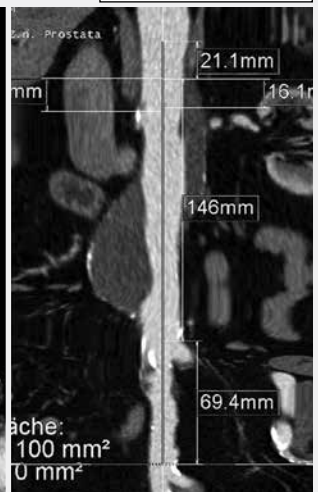
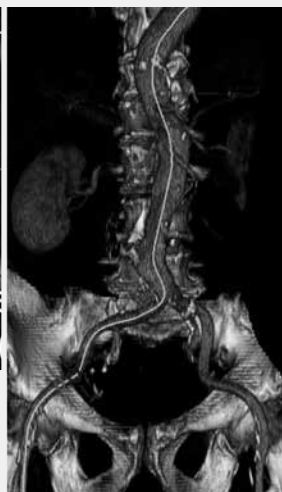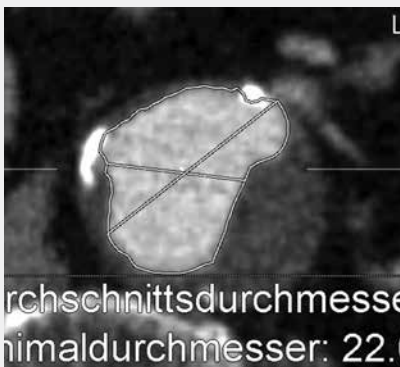
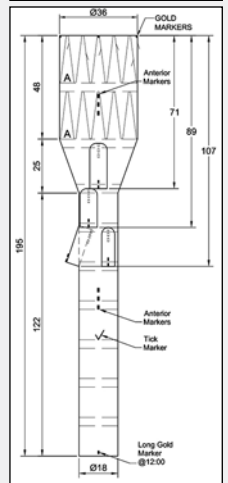
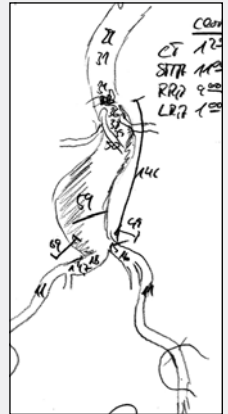
4-CMD-BEVAR for a thoracoabdominal aneurysm type 4 – Bridging stentgrafts: VBX

Operators: M. Austermann, M. Bosiers, S. Mühlenhöfer

Clinical data: Art. hypertension, CAD, deep vein thrombosis and LE 10/2018, prostate carcinoma 2014 healed

Important items: Incidental finding of the aneurysm during therapy of the LE

- Procedural steps:**
1. Left axillary access 5F sheath via cut down
 2. Percutaneous approach both groins (Prostar XL, ABBOTT) 14F (COOK) both groins
 3. Lunderquist wire through the right groin
Pig tail catheter through the left groin for imaging
Registration of the Fusion technology
 4. Placement of the CMD-branched-endograft (COOK) with 4 branches by using the Fusion system
 5. Placement of the bifurcated graft: Unibody (COOK) and the iliac extensions
Then closure of the groins to avoid paraplegia
 6. Connection of all targetvessels through the corresponding branches using Viabahn BX (GORE) from above
 7. Closure of the axillary access



Case 43 – MUN 04: male, 82 years (W-K)

Double Chimney EVAR in order to extent a existing bifurcated endograft with insufficient proximal sealing and growing aneurysm

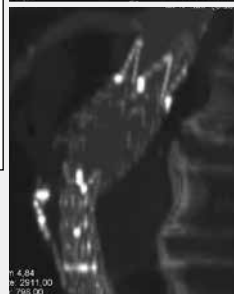
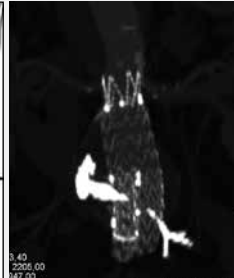
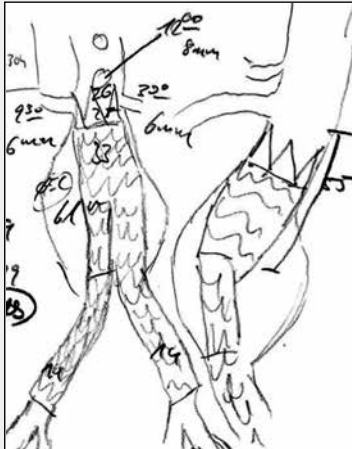
Operators: M. Austermann, E. Beropoulos, M. Mühlenhöfer

Clinical data: CAD, MI and PTCA 2007, art. hypertension

Present state: Previous Onyx Embolization of type2 EL's
Still growing aneurysm
Degeneration of the aneurysm neck with loss of sealing

Procedural steps:

1. Cut down left axillary artery and double puncture
2. Placement of two 7F Shuttle sheaths from above
3. Percutaneous approach right groin Prostar XL 10F (ABBOTT)
Placement of 14F sheaths (COOK)
Puncture of the left groin for imaging through a 5F sheath
4. Cannulation of both renal arteries from above
5. Placement of the Endurant aortic extension ETCF 36 36 C 49 (MEDTRONIC)
6. Placement of the Chimney stent-grafts in both renal arteries: Advanta V12 (GETINGE)
7. Closure of the accesses



Case 44 – FRA 01: male, 74 years

Percutaneous CT-guided microwave ablation of hepatocellular carcinoma post TACE therapy

Operators: N. A. Nour-Eldin, E. Elhawash

Clinical data: Alcohol induced liver cirrhosis. 2 hepatocellular carcinoma lesions, one lesion in segment 7 and the other lesion in segment 3. The patient received 3 cycles of TACE for tumor downsizing followed by microwave ablation of the HCC lesion in Segment 7. Today Ablation therapy of the HCC lesion in Segment 3.

Present state: Minimal ascites
Portal hypertension
Low platelet count. 40.000/cc
The lesion is near the liver hilum

- Procedural steps:**
1. Revision of the previous images for confirmation of the size and location of the lesion
The targeted lesion is at segment 3 subcapsular
 2. Non contrast enhanced CT scan of the liver for planning
The lipiodol uptake within the lesion by previous TACE facilitates the localization of the under CT guidance.
 3. Surface marking of the location of the lesion as well as the site of puncture on the skin
 4. Sterile covering followed by infiltration of the local anesthetic
Conscious sedation would be given
 5. Stepwise insertion of the Microwave antenna
(Covidien Emprint Ablation System, MEDTRONIC) within the lesion
 6. The energy required for ablation will be given
to induce complete ablation of the lesion
Intermittent CT images to observe the changes during the ablation procedure
 7. After applying the required energy for ablation, needle track ablation will be done followed by removal of the antenna

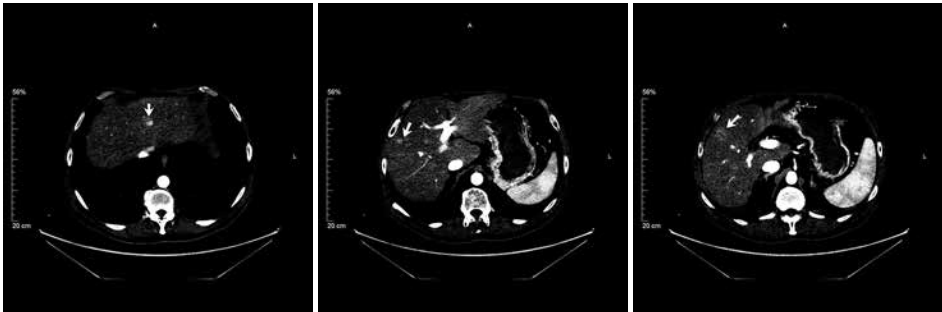
Case 45 – JEN 01: male, 63 years (D-J)

Selective internal radiation therapy in hepatocellular carcinoma

Operators: R. Aschenbach, S. Witting, R. Drescher

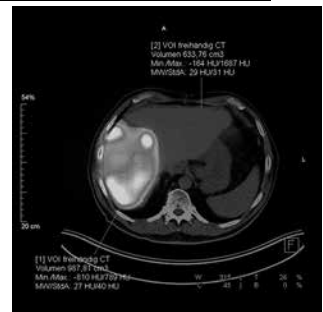
Clinical data: HCC Stage IIIa (pT3 Nx Mo) 6/18
 Atypical segmentectomy segment III 6/18
 cTACE performed in referring hospital
 Multifocal HCC in both liver lobes
 Primary outside MILAN
 Universal liver tumor board waived sequential SIRT, starting right
 Evaluation showed a 2.5% shunt to the lung and estimated dose
 of 2.5GBq for Therasphere (BTG)
 No extrahepatic deposition of radioactivity in test-dose

Risk factors: Liver cirrhosis CHILD A, MELD 6
 Diabetes mellitus, arterial hypertension



Procedural steps:

1. **Right groin retrograde access**
 - 0.035" EMERALD guidewire 150 cm (CORDIS)
 - 5F 10 cm Radiofocus Introducer II sheath (TERUMO)
2. **Placement of diagnostic catheter in main hepatic artery**
 - 0.035" Radiofocus angled guidewire, 180 cm (TERUMO)
 - Diagnostic catheter SIM 1, 4F 0.035", 100 cm (CORDIS)
3. **Placement of microcatheter in right hepatic artery**
 - Progreat 2.7F (TERUMO)
 - alternative wire: Cirrus 14' (COOK)
4. **Radioembolisation**
 - SIRT with TheraSphere® yttrium-90 glass microspheres (BTG)
5. **Puncture site occlusion**
 - Vascularclosure Device Exoseal (CORDIS)



Case 46 – JEN 02: female, 58 years (H-L)

Transarterial chemoembolization with drug-eluting-beads (DEB-TACE) in hepatocellular carcinoma

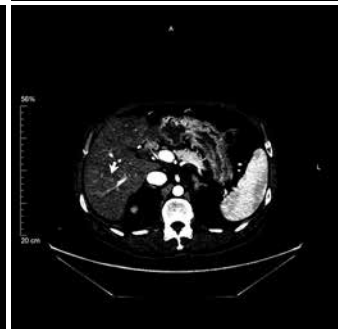
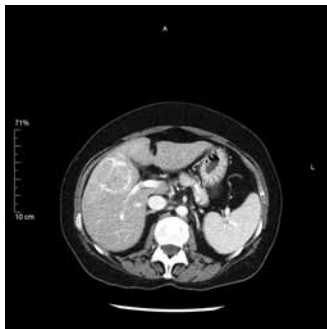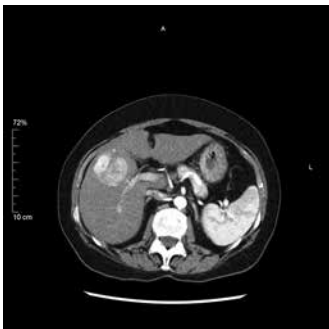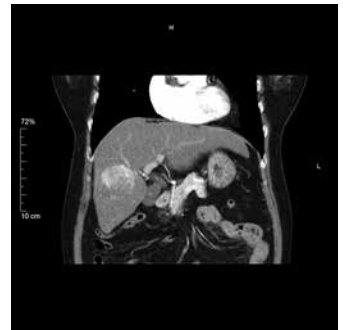Operators: R. Aschenbach, S. Witting

Clinical data: Differentiated hepatocellular carcinoma (G1)

Risk factors: Liver cirrhosis CHILD A
Chronische hepatitis

Procedural steps:

1. **Right groin retrograde access**
 - 0.035" EMERALD guidewire 150 cm (CORDIS)
 - 5F 10 cm Radiofocus Introducer II sheath (TERUMO)
2. **Placement of diagnostic catheter in main hepatic artery**
 - 0.035" Radiofocus angled guidewire, 180 cm (TERUMO)
 - Diagnostic catheter Cobra 4, 4F 0.035", 100 cm (CORDIS)
3. **Placement of microcatheter in right hepatic artery**
 - Progreat 2.7F (TERUMO)
 - alternative wire: Cirrus 14' (COOK)
4. **Superselective placement of microcatheter in feeding artery**
5. **Embolization**
 - 40µm Embozene-Tandem (BOSTON SCIENTIFIC) loaded with 150 mg Doxorubicin till stasis
6. **If still perfusion after administration of the whole 3ml Embozene Tandem 40µm then additional embolization with blande microparticals Embozene 400µm till stasis is reached**
7. **Control angiography**
8. **Puncture site occlusion**
 - Vascular closure device Exoseal (CORDIS) and pressure dressing



Transjugular intrahepatic portosystemic shunt revision with coil embolization of esophageal varices

Operators: N. A. Nour-Eldin , N. Naguib , E. Elhawash

Clinical data: Liver cirrhosis, portal hypertension, refractory ascites, bleeding varices. TIPS-Dysfunction.

CT-scan: Dilated portal vein, gastero-oesophageal varices, ascites

- Procedural steps:**
1. Sterile covering of the patient
 2. US-guided puncture of the right internal jugular vein
 3. Insertion of the 10F vascular sheath (Super Arrow-Flex, TELEFLEX)
 4. Using the Multipurpose catheter (CORDIS), cannulation of the right hepatic vein
 5. Cannulation of the TIPS-Shunt, using Multipurpose catheter (CORDIS) or Sidewinder 1 (TERUMO).
 6. Puncturing of the portal vein using the TIPS-System (OPTIMED).
 7. After passing the guide-wire pushing a 4F catheter (Perlstein-Catheter).
 8. Performance of direct portography
Measurement of the portal vein pressure as well as the CVP.
 9. elective catheterization of esophageal varices using microcatheter (Progreat, Terumo). Embolization of the varices using Penumbra Coils (Penumbra Company)
 10. Demonstration of the flow within the TIPS.
 11. Redilatation of the TIPS Stent followed by elongation of the stent (Viator-Stent).
 12. Demonstration of the flow within the TIPS and measurement of the Pressures.
 13. Removal of materials and insertion of a Sheldon-Catheter.

Case 48 – COL 04: female, 52 years (A-B)

Long SFA occlusion with hx of iliac stenting

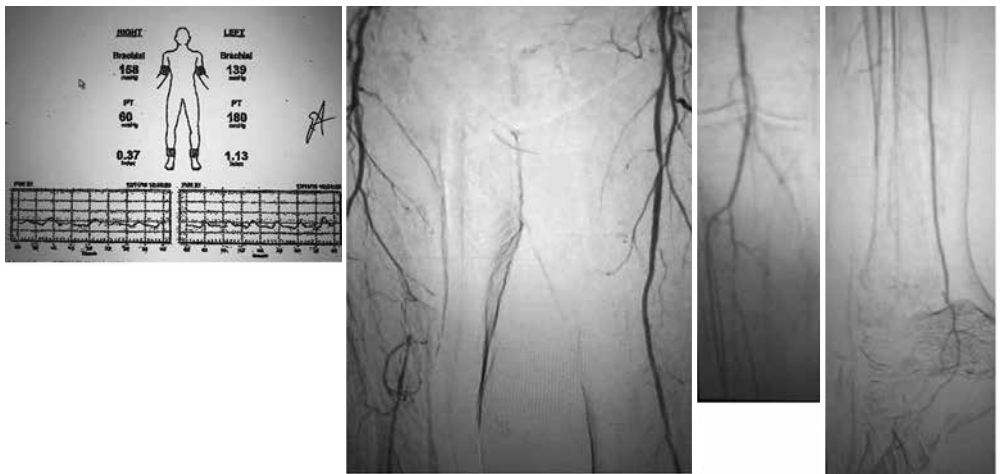
Operators: G. Ansel, C. Huff, M. Jolly, M. Silver

Clinical data: 52 year old female with history of 3 months of rest pain to the lower extremity. Previous history of common iliac stenting 12 years ago.

Risk factors: Long history of smoking and continues to smoke 1.5 pks/day. PMX = Essential hypertension, hyperlipidemia.

Present state: ABI .37 and .11

- Procedural steps:**
1. Contralateral femoral ultrasound guided access, placement of a 7 french braided sheath.
 2. Will attempt hydrophilic wire traversal, if unsuccessful will utilise re-entry catheter
 3. Predilation with undersized balloon, and if reasonable predilation result will dilate with POBA 1:1 to native vessel, if that has a acceptable result will use DCB 1 mm larger. If any predilation problems will use DES or if more focal continue on with DCB with plan to spot stent
 4. Will then proceed to POBA tibioperoneal trunk which has a high grade stenosis and post tibial is main vessel to foot
 5. If dissection with use coronary DES
 6. Sheath removal with suture based device



Prostatic artery embolization for symptomatic benign prostatic hyperplasia

Operators: T. Franiel, F. Bürckenmeyer

Clinical data: Prostatic volume 80 ml
 Negative TRUST-guided systematic biopsy due to increased PSA 6.0
 IPSS: 19 (0-35), QoL: 3 (0-6), Qmax: 13.0 ml/s with voided volume of 160 ml
 IIEF-5: 15 (1-25)

Risk factors: Arterial hypertension

Duplex: Post void residual urine of 100ml

Present state: Lower urinary tract symptoms due to BPH (confirmed by urology department)
 No successful medication therapy for more than 6 month, refusing operative therapy

Procedural steps:

1. **Right groin access**
 - St. Jude (ABBOTT)
2. **Placement of coaxial catheter in distal aorta**
 - RIM 4F (CORDIS) or alternative (MERRIT MEDICAL)
 - Alternative wire: Cirrus 14" (COOK)
3. **Large-FOV-dyna CT for determination of anatomy and origins of the prostatic arteries**
4. **Placement of microcatheter in the left prostatic artery for embolization**
 - Progreat 2.7F (TERUMO), alternative: Progreat 2.0F alpha (TERUMO), alternative SwiftNinja (MERRIT MEDICAL)
 - Embozene 250 µm (BOSTON SCIENTIFIC), alternative: 400 µm (BOSTON SCIENTIFIC)
5. **Placement of the microcatheter in the right prostatic artery for embolization**
 - Progreat 2.7F (TERUMO), alternative: Progreat 2.0F alpha (TERUMO), alternative SwiftNinja (MERRIT MEDICAL)
 - Embozene 250 µm (BOSTON SCIENTIFIC)

Case 50 – FRA 03: female, 53 years

Uterine artery embolization for fibroids and adenomyosis

Operators: N. Naguib, N. Nour-Eldin

Clinical data: Adenomyosis, Multiple fibroids, Dysmenorrhia, Menorrhagia (excessive bleeding), Pressure symptoms on the urinary bladder.

Procedural steps:

1. Performance of contrast enhanced MRA of the pelvic arteries
2. Puncture of the right femoral artery in Seldinger's technique followed by application of a 5F sheath (TERUMO)
3. Performance of pelvic angiography using Pigtail catheter
4. Selective catheterisation of the right uterine artery using sidewinder-1 cath using microcatheter (Progreat, TERUMO) with superselective demonstration of the right uterine artery
5. Injection of the Embozene particles (700-900 microns) through the microcatheter till stasis
6. Then catheterization of the left uterine artery using sidewinder-1 and Progreat microcatheter (TERUMO)
7. Injection of the Embozene microsphere particles (500-700 microns, BOSTON SCIENTIFIC) through the microcatheter till stasis
8. Removal of the catheters and closure of femoral puncture using angioseal system

Case 51 – JEN 04: female, 74 years (V-5)

Aneurysma embolization (coiling) of the splenic artery

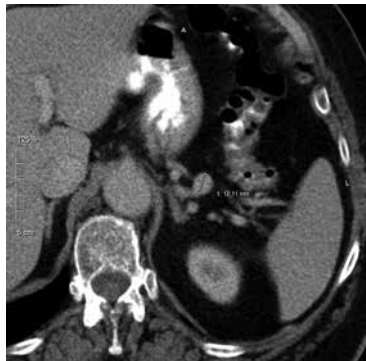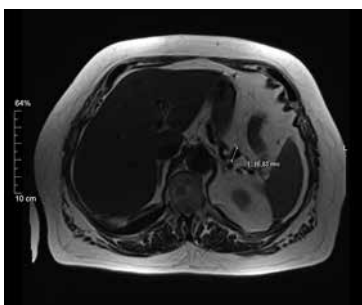
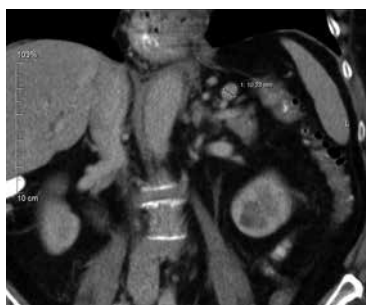Operators: F. Bürckenmeyer, I. Diamantis

Clinical data: 16 mm neurysm of the lienal artery with growth tendency

Risk factors: Arterial hypertension, rheumatoid arthritis

Procedural steps:

1. **Right groin retrograde access**
 - 0.035" EMERALD guidewire 150 cm (CORDIS)
 - 5F 10 cm Radiofocus Introducer II sheath (TERUMO)
2. **Placement of diagnostic catheter in main hepatic artery**
 - 0.035" Radiofocus angled guidewire, 180 cm (TERUMO)
 - Diagnostic catheter Cobra 4, 4F 0.035", 100 cm (CORDIS)
3. **Placement of microcatheter in splenic artery**
 - Progreat 2.7F (TERUMO)
 - alternative wire: Cirrus 14' (COOK)
4. **Embolization**
 - PENUMBRA Coils system
5. **Control angiography**
6. **Puncture site occlusion**
 - Vascular Closure System Exoseal (CORDIS) and pressure dressing



Case 52 – FRA 04: male, 64 years

Chemoembolization of HCC in segment 6

Operators: N. Nour-Eldin, E. Elhawash

Clinical data: Male patient. Hepatitis B induced HCC in segment 6.

Procedural steps:

1. Revision of MRI and CT images for demonstration of the size and location of HCC.
2. Puncture of the right femoral artery in Seldinger's Technique followed by application of a 5F sheath (TERUMO).
3. Performance of direct angiography of the coeliac trunk using Sidewinder catheter
4. Selective catheterisation of the common hepatic artery
5. Superselective catheterization of the arteries supplying the tumors using Progreat microcatheter (TERUMO)
6. Injection of the chemotherapy: Mitomycin c (10 mg), Cisplatin (50 mg) and Lipoiodol 5-10 ml
7. Demonstration of the hepatic artery post embolization.
8. Removal of the catheters and closure of femoral puncture using angioseal.

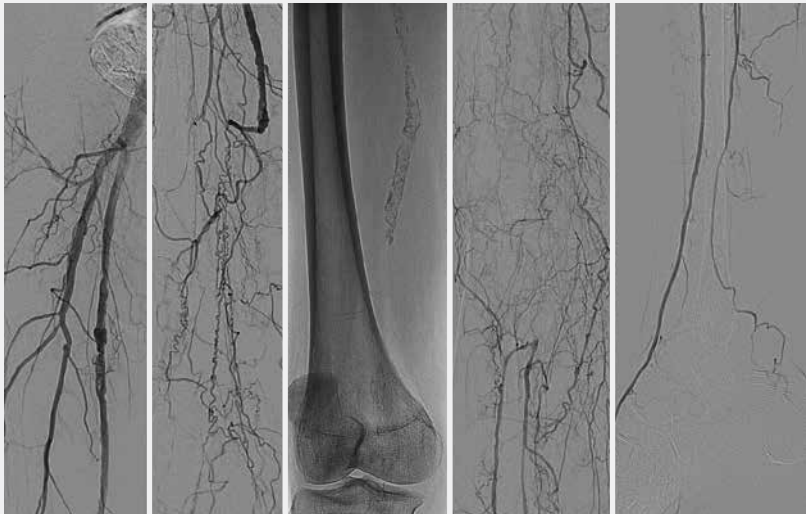CTO, multilevel disease right

Operators: A. Schmidt, M. Ulrich

Clinical data: PAOD Rutherford class 4, claudication right calf, walking capacity 50 m, restpain during night, ABI right 0.52, EVAR and stenting right renal artery 11/2018, chronic pancreatitis
Failed recanalization attempt right popliteal 12/18 elsewhere

Risk factors: Arterial hypertension, hyperlipidemia

- Procedural steps:**
1. **Antegrade approach right groin**
 - 7F 55 cm Flexor sheath (COOK)
 2. **Antegrade guidewire passage**
in case of failure retrograde approach via the proximal anterior tibial artery
 - 2.9F sheath (pedal puncture set) (COOK)
 - 0.014" CTO-Approach 25 gramm guidewire, 300 cm (COOK)
 - 0.018" CXI support catheter 90 cm (COOK)
 - Advance Micro-Balloon 3.0/120 mm, 90 cm (COOK)
 3. **Atherectomy of the popliteal artery**
 - JetStream atherectomy device (BOSTON SCIENTIFIC)
 4. **Angioplasty**
 - VascuTrak 4.0/120 mm balloon (BARD)
 - Luminor DCB (iVASCULAR)
 5. **Stenting on indication**
 - Spot-stenting with Multi Lock (B.BRAUN)



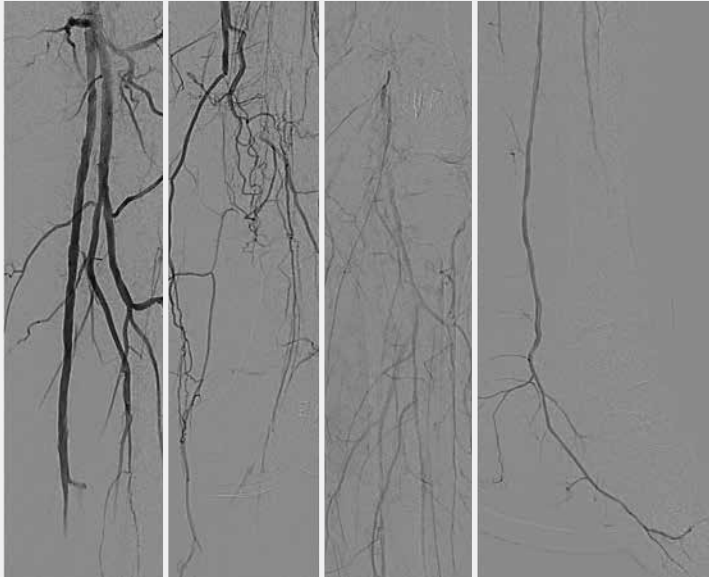
Case 54 – LEI 18: female, 67 years (B-U)

Long occlusion of the left popliteal artery

Operators: S. Bräunlich, J. Schuster

Clinical data: PAOD Rutherford 3, claudication left calf, walking capacity 30 m
ABI left 0.3
Hypothyreosis

Risk factors: Arterial hypertension, current smoker, hypelipidemia



Procedural steps:

1. **Right groin cross-over approach**
 - Judkins Right 5F diagnostic catheter (CORDIS/CARDINAL HEALTH)
 - 0.035" SupraCore guidewire 30 cm (ABBOTT)
 - 6F 55 cm Balkin Up&Over sheath (COOK)
2. **Guidewire passage of the occlusion and PTA with DCBs**
 - 0.014" Command ES guidewire, 300 cm (ABBOTT)
 - 0.018" 90 cm Seeker support catheter (BARD)
 - 0.014" Ultraverse balloon (BARD)
 - Lutonix-BTK DCB (BARD)
3. **In case of dissections after DCB, provisional placement of nitinol "tacks"**
 - Tack Endovascular System (Intact Vascular)

LEIPZIG
INTERVENTIONAL
COURSE
2019

L I N C

Thursday,
January 24, 2019

Thursday

Case 55 – ABT 01: male, 73 years (P-C)

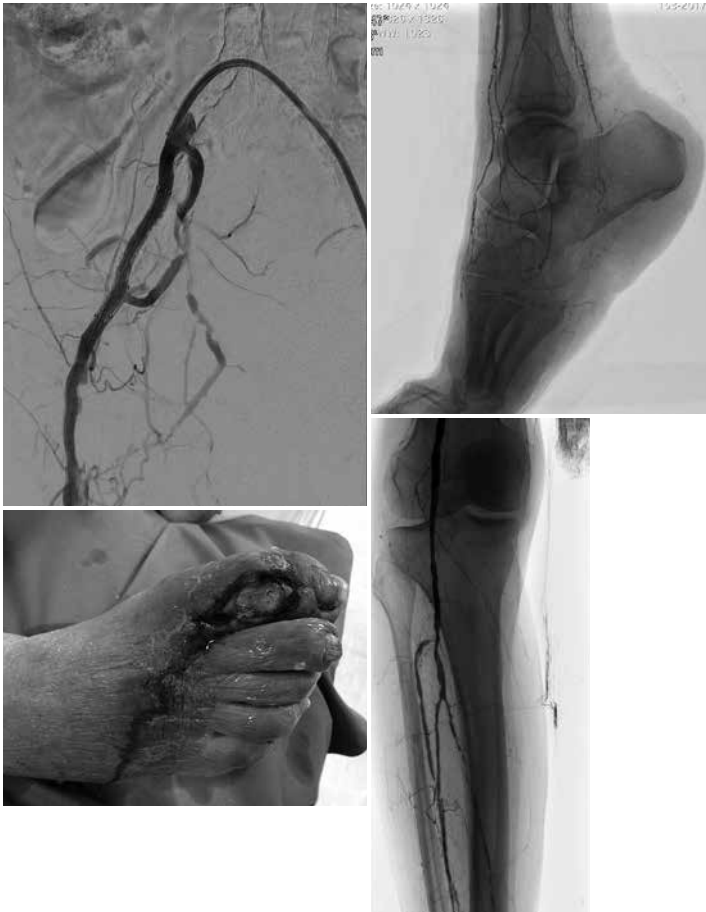SAD trasmission case

Operators: M. Manzi, S. Fereire Diaz

Clinical data: Tuc 3D lesion in right I° toe; TcPO₂ = 18 mmHg.
BTK and BTA calcificated occlusions SAD.

Risk factors: DM, hypertension, cardiac ischemic disease

- Procedural steps:**
1. Antegrade CFA US guided puncture and TERUMO 11 cm sheath deployment; 2D perfusion angio
 2. AT 0.014 Intraluminal recanalization and POBA Coyote ES, Coyote, BOSTON SCIENTIFIC
 3. Outflow evaluation; 2D perfusion angio and discussion
 4. US guided closure device deployment 6F Angio-Seal



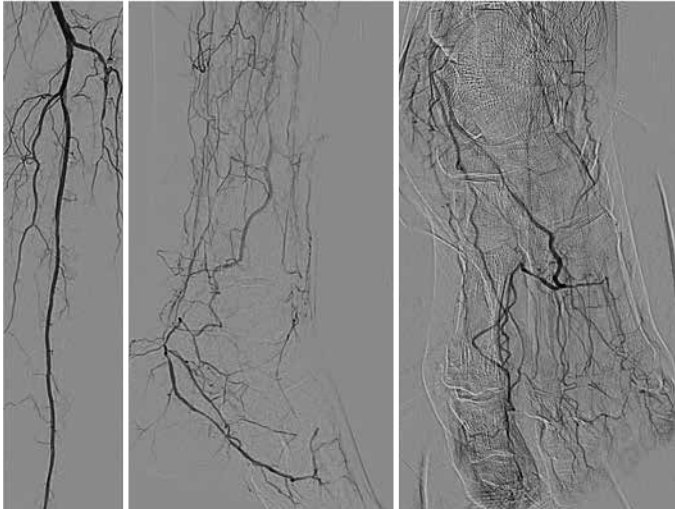
Case 56 – LEI 19: female, 74 years (M-C)

Complex BTK-CTO in a CLI-patient

Operators: A. Schmidt, A. Fischer

Clinical data: Critical limb ischemia, minor gangrene dig 1 left, restpain and severe claudication left, ABI left 0.2
Multiple interventions both legs, D4-Amputation right 11/2018

Risk factors: Art. Hypertension, diabetes mellitus type 2 with multiple complications



Procedural steps:

1. **Antegrade approach left groin**
 - 6F 55 cm sheath (COOK)
2. **Guidewire passage antegrade into posterior tibial artery**
 - 0.014" Command (ABBOTT)
 - 0.014" PT2 guidewire 300 cm (BOSTON SCIENTIFIC)
 - In case of failure: retrograde approach
3. **PTA**
 - Vessel preparation – scoring balloon (VascuTrak, BARD)
 - Lutonix BTK DCB (BARD)
4. **In case of dissections after DCB, provisional placement of nitinol "tacks"**
 - Tack Endovascular System (INTACT VASCULAR)

Case 57 – LEI 20: female, 72 years (R-V)

Subacute occlusion left SFA

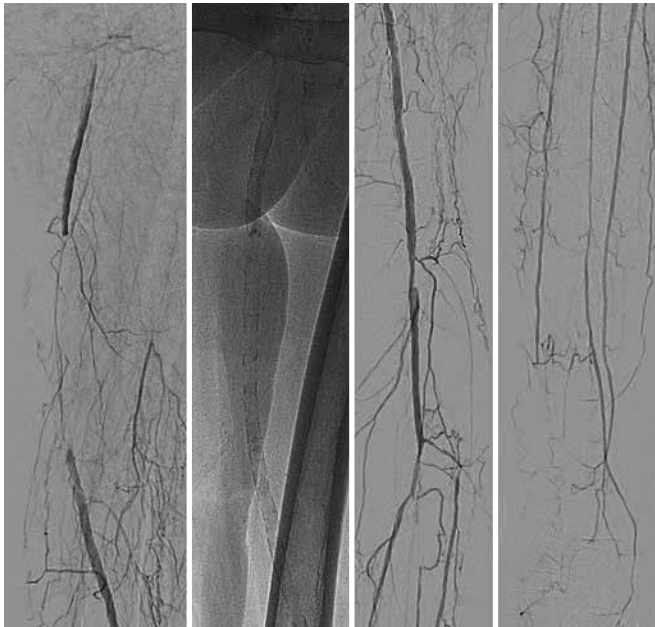
Operators: A. Schmidt, A. Fischer

Clinical data: Critical limb ischemia bilateral, ulcerations both feet (right forefoot, left lateral foot)
ABI left 0.54, Rutherford class 5
PTA right SFA 12/2018
Iliac stenting 2013/2014
CAD with PTCA 2018
CEA right internal carotid artery 2015
Renal transplantation 2006

Risk factors: Art. hypertension, diabetes mellitus type 2

Procedural steps:

- 1. Right femoral retrograde and cross-over approach**
 - 8F Balkin Up&Over 40 cm sheath (COOK)
- 2. Guidewire passage**
 - 0.018" Command 18 guidewire, 300 cm (ABBOTT)
- 3. Rotarex-thrombectomy**
 - 8F (STRAUB MEDICAL)
- 4. PTA/stenting on indication**
 - Pacific 5/120 mm balloon (MEDTRONIC)
 - Eluvia DES 6.0/120 mm stent (BOSTON SCIENTIFIC) or Zilver PTX (COOK)



Case 58 – LEI 21: male, 65 years (L-P)

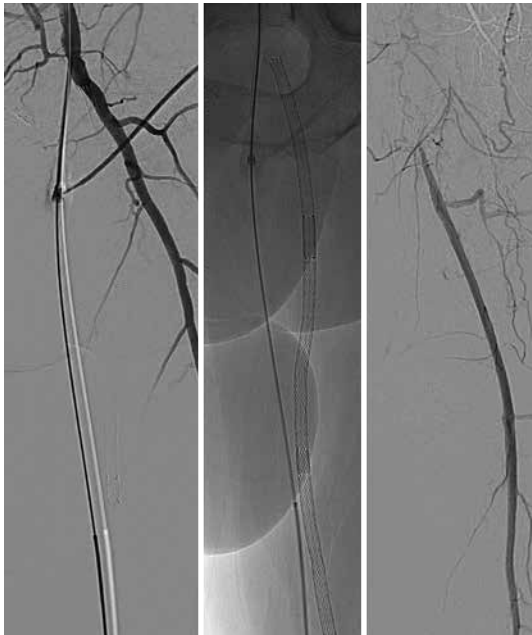
Chronic in-stent reocclusion left SFA

Operators: S. Bräunlich, J. Schuster

Clinical data: Severe claudication left calf, walking capacity 200 meters
 ABI left 0.68, Rutherford class 3
 PTA/stenting left SFA 2015 (Zilver-PTX)
 PTA right SFA, DCB-treatment 12/2018
 Dilatative cardiomyopathy, EF 35%

Risk factors: Arterial hypertension, former smoker

Angio: Complete in-stent reocclusion left SFA



Procedural steps:

1. **Right groin retrograde and cross-over approach**
 - 8F Balkin Up&Over sheath (COOK)
2. **Guidewire passage**
 - 0.018" Command 18, 300 cm (ABBOTT)
 - 0.018" Quick-Cross support catheter, 135 cm (PHILIPS)
3. **Thrombectomy**
 - Rotarex 8F (STRAUB MEDICAL)
4. **PTA**
 - Luminor 5,0/200 mm DCB (IVASCULAR)
 - potentially with filter protection Spider-filter 6 mm (MEDTRONIC)

Case 59 – MUN 05: female, 34 years (G-A)

Chronic central venous occlusion of the anonymous vein treated by covered stent

Operators: A. Schwindt, S. Mühlenhöfer

Clinical data: Multiple skleroses since 2015, plasmapheresis via central venous catheter since 2016, central venous catheter removal 06/2018 due to thrombosis of right anonymous vein

Present state: Chronic swelling of right arm and neck due to venous CTO of right anonymous vein

Procedural steps:

- 1. Duplex guided puncture and access via right common femoral vein and right subclavian vein**

- Insertion of 5F 90 cm shuttle sheath femoral (COOK) and 8F 45 cm destination sheath via subclavian vein

- 2. Recanalization of anonymous vein occlusion**

- Command 18 wire (ABBOTT) and 0,018" Quickcross catheter (PHILIPS)

- 3. Predilatation**

- 4 mm ULTRAVERSE balloon (BARD)

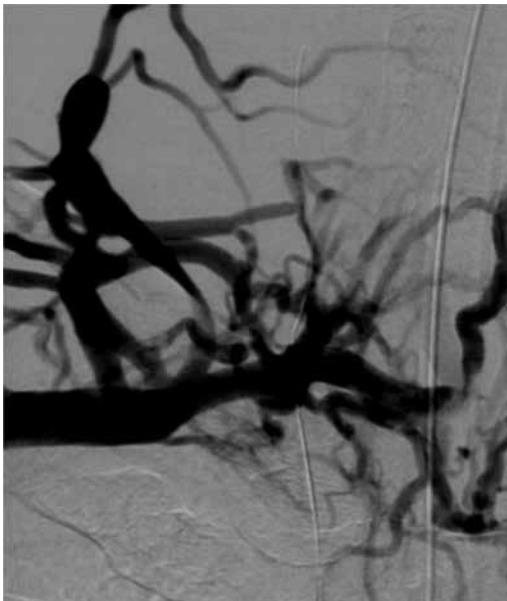
- 4. Stent implantation**

- 10 mm COVERA covered stent (BARD)

- 5. Postdilatation**

- 10 mm CONQUEST high pressure balloon

- 6. Access management by manual compression and pressure dressing**



Case 60 – LEI 22: male, 76 years (D-A)

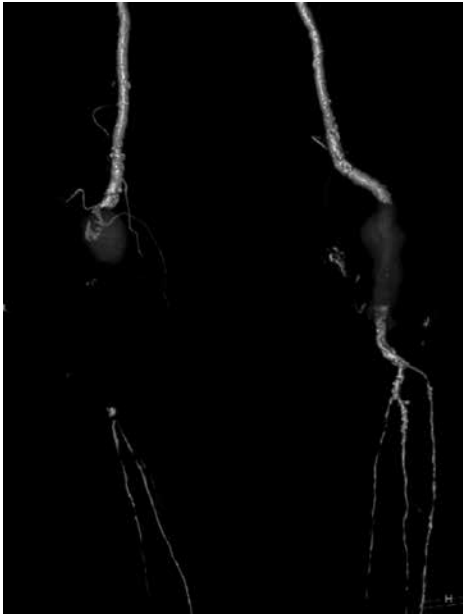
Aneurysm of the left popliteal artery

Operators: A. Schmidt, M. Ulrich

Clinical data: Progredient aneurysm left popliteal, right popliteal occlusion, claudication after 50m right
Artrial fibrillation, intra-cerebral bleedings 2017, apoplexia 12/2018

Risk factors: Art. hypertension, nicotine abuse

MRA: Aneurysm of the left popliteal artery (35 mm), popliteal occlusion right



Procedural steps:

- 1. Left antegrade access**
 - 9F 55 cm Flexor Check-Flo sheath, Raabe Modification (COOK)
- 2. Guidewire passage from antegrade**
 - 0.035" Radiofocus soft angled guidewire, 260 cm (TERUMO)
 - CXI support catheter, 0.035" 135 cm (COOK)
- 3. Viabahn implantation of the left popliteal artery**
 - 10/150 + 13/100 Viabahn (GORE)
 - 6/40 Admiral Extreme (MEDTRONIC)

Case 61 – BK 01: female, 71 years (O-E)

CFA, SFA and popliteal artery atherectomy plus DCB angioplasty

Operators: E. Noory

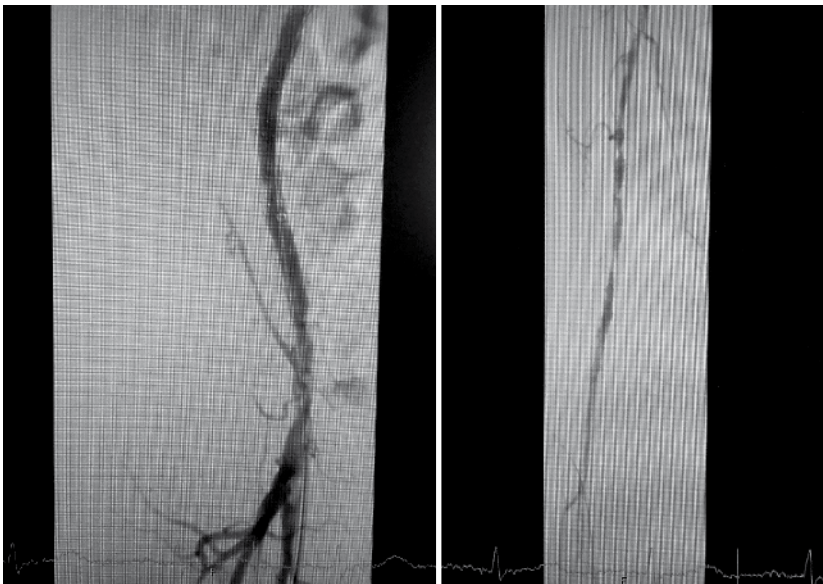Clinical data: PAOD Fontaine IV / Rutherford 5 both legs
Stent angioplasty distal infrarenal aorta & DCB SFA left leg 12.12.2018
Recanalisation & stentimplantation both CIA & EIA and SFA recanalisation left leg 2011
ABI non-diagnostic due to mediocalcification

Risk factors: Hypertension, hyperlipidemia

Duplex: Moderate stenosis of right CFA & SFA origin, high grade stenosis of popliteal artery

Procedural steps:

1. **7F cross-over sheath**
2. **Lesion crossing**
 - 0.035" Glidewire (TERUMO) guided by a 5F vertebral catheter (CORDIS)
3. **Embolic protection**
 - Introduction of a Spider embolic protection system (MEDTRONIC)
4. **Atherectomy**
 - Directional atherectomy (HawkOne, MEDTRONIC) of CFA, SFA origin, and popliteal artery
5. **Angioplasty**
 - Drug coated balloon angioplasty (IN.PACT Pacific , MEDTRONIC or Tulip, ACOTEC)
6. **Sheath removal with closure device**
 - Femoseal (TERUMO)



OCT-guided atherectomy of popliteal CTO

Operators: A. Schwindt, S. Mühlenhöfer

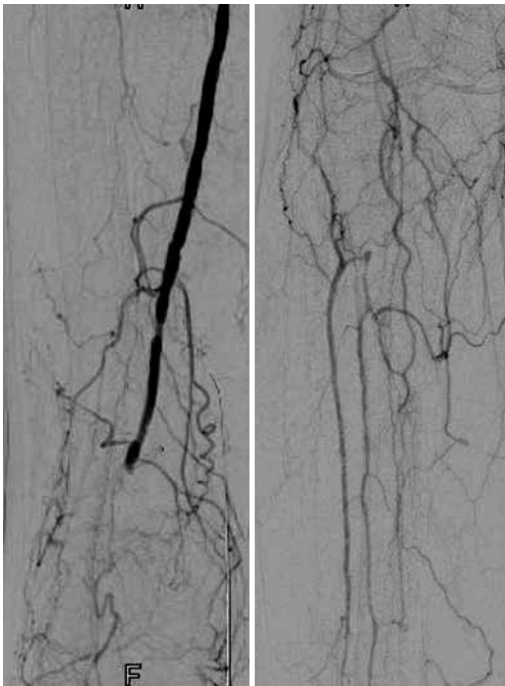
Clinical data: CLI right leg since 10/2018 with ischemic ulcer of the forefoot and restpain, wd 15 meters
ABI right leg 0,32

Risk factors: Arterial hypertension, atrial fibrillation

Angiogramm: CTO of popliteal artery, anterior tibial and posterior tibial

Procedural steps:

1. **Antegrade right femoral approach**
 - 5F 10 cm sheath (TERUMO)
 - Change for 6F 45 cm destination sheath (TERUMO)
2. **Recanalization of popliteal CTO**
 - Command 0,018" wire (ABBOTT) and 0,018" Quickcross (PHILIPS)
 - if necessary retrograde puncture of anterior tibial and rendezvous technique
3. **OCT-guided atherectomy**
 - Pantheris 6F (AVINGER)
 - Protection of outflow with 4 mm Spiderfilter (MEDTRONIC)
4. **Post PTA**
 - 4F 5 mm Passeo LUX DCB (BIOTRONIK)



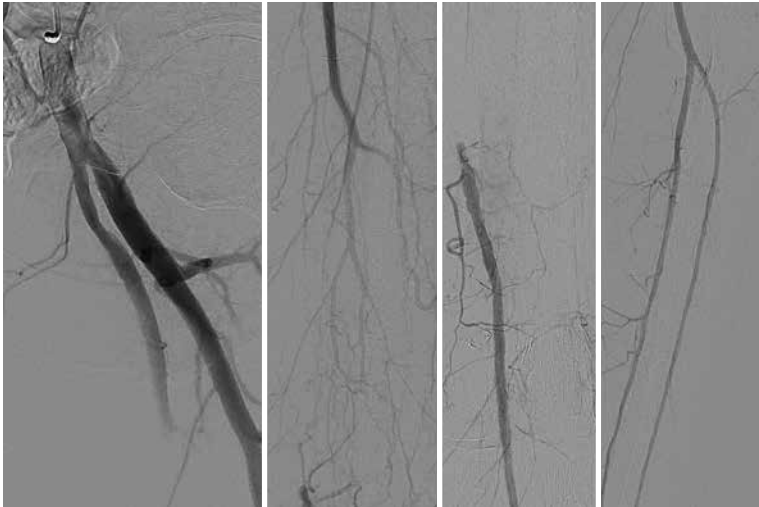
Case 63 – LEI 23: male, 53 years (H-B)

Long SFA-occlusion left, moderate calcification

Operators: M. Ulrich, A. Fischer

Clinical data: PAOD Rutherford class 3, claudication left calf, walking capacity 150 m, ABI left 0.65
Failed recanalization attempt (thrombectomy) 07/18 elsewhere

Risk factors: Arterial hypertension, hyperlipidemia, current smoker



Procedural steps:

1. **Right femoral access and cross-over approach**
 - 6F 45 cm cross-over sheath Fortress (BIOTRONIK)
2. **Passage of the occlusion left SFA**
 - 0.035" Radiofocus angled stiff guidewire, 260 cm (TERUMO)
 - 0.035" CXC support catheter, 135 cm (COOK)

In case of failure guidewire passage from antegrade:
3. **Retrograde approach via distal ATA**
 - 7 cm 21 Gauge needle (COOK)
 - 0.018" V-18 Control guidewire, 300 cm (BOSTON SCIENTIFIC)
 - 4F 10 cm Radiofocus introducer (TERUMO)
 - Pacific Plus 4.0/40 mm balloon, 90 cm (MEDTRONIC)
4. **PTA with DCBs**
 - Passeo 18 balloon 5 x 150 mm (BIOTRONIK)
 - 5 mm Passeo 18 Lux DCB (BIOTRONIK)
5. **Stenting on indication**
 - Pulsar 18-T3 stent (BIOTRONIK)

Case 64 – BK 02: male, 79 years (K-W)

Lithotripsy, DCB angioplasty and provisional stenting with a 3D helical nitinol stent

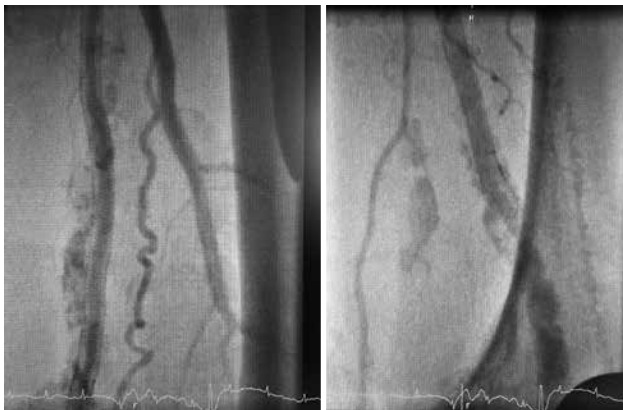
Operators: E. Noory

Clinical data: PAOD Fontaine IIb/ Rutherford 3 left leg
 DCB angioplasty CFA & SFA instent right leg 13.12.2018
 Rotarex-recanalisation & DCB SFA, popliteal artery, TPT and PTA left leg 09/2016
 DCB SFA, popliteal artery & TPT left leg 10/2012
 Recanalisation left SFA 09/2010
 Stent-recanalisation SFA right leg 05/2010
 Coronary 3-vessel disease
 Quadruple CABG 05/2014
 ABI 0.9/0.6

Risk factors: Hypertension, hyperlipidemia, diabetes mellitus type 2, obesity, ex-smoker

Duplex: Calcified high grade stenosis of distal SFA/popliteal artery left leg

- Procedural steps:**
1. **Antegrade left femoral access**
 - 7F Avanti sheath (CORDIS)
 2. **Lesion crossing attempt**
 - 0.014" Advantage wire (TERUMO)
 3. **Lithotripsy**
 - Shockwave balloon 6.5/60 mm (SHOCKWAVE)
 4. **DCB angioplasty**
 - Tulip (ACCOTEC)
 5. **Stent implantation on indication**
 - MultiLoc (BAYER)
 6. **Sheath removal**
 - Closure device Femoseal (TERUMO)



Case 65 – ABT 02: male, 83 years (Q-A)

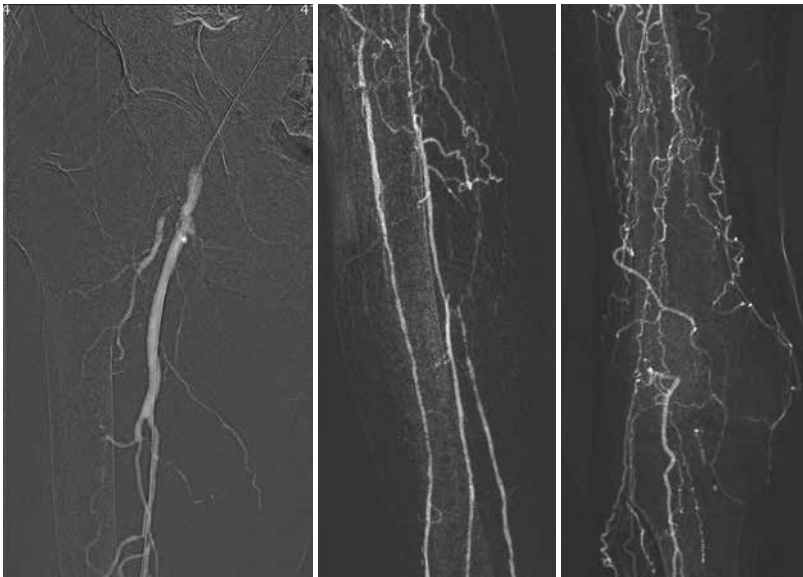
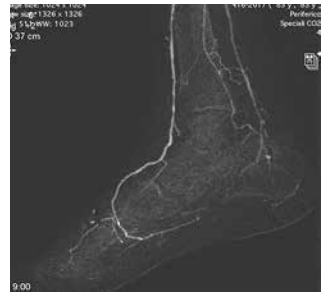
Long SFA occlusion with short stump at the ostium

Operators: M. Manzi, S. Fereire Diaz

Clinical data: Right foot rest pain, TcPO₂ 27 mmHg

Risk factors: DM, hypertension, dyslipidemia

- Procedural steps:**
- 1. Antegrade US puncture**
 - 6F 11 cm sheath (TERUMO)
 - 2D Perfusion angio
 - 2. Guidewire passage**
 - Antegrade intraluminal/subintimal 0,018 Vi8 CW (BOSTON SCIENTIFIC) SFA recanalization
 - retrograde Proximal AT puncture when failure
 - 3. Predilatation at 3 mm**
 - Non Compliant BARD Dorado
 - 5 mm x 200 mm POBA
 - 4. Spot stenting and bail-out**
 - 5. 2D Perfusion angio and discussion**
 - 6. US guided closure**
 - 6F Angio-Seal



Case 66 – MUN 07: male, 55 years (T-K)

TEVAR extension after endovascular aortic arch repair with A-Branch 9/2017 after open repair of the asc. Aorta 7/2014

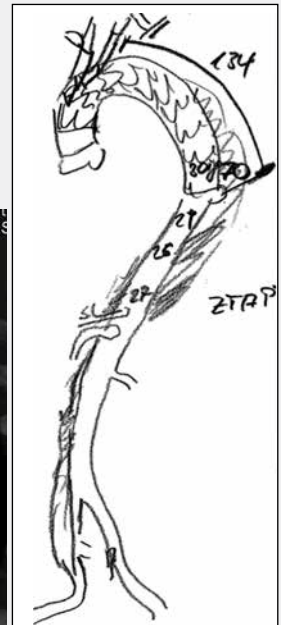
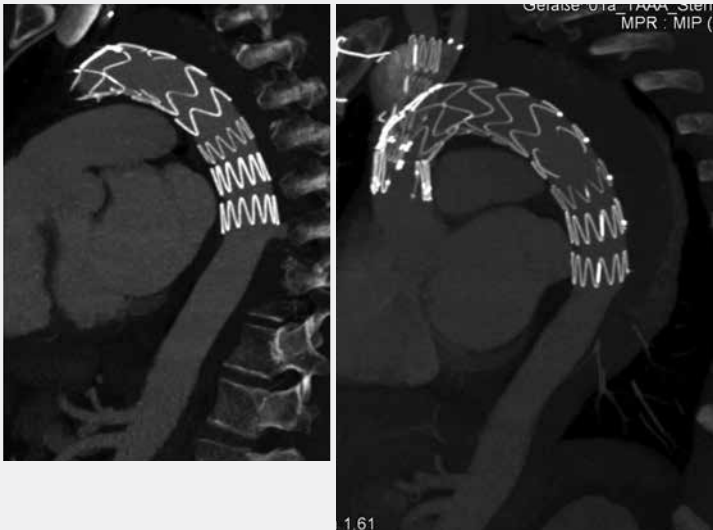
Operators: M. Austermann, E. Beropoulos

Clinical data: Atrial fibrillation, art. hypertension, chron. back pain

Present state: Growing false lumen aneurysm due to a new reentry tear at the end of the existing endograft

Procedural steps:

- 1. Percutaneous approach both groins**
 - 5F sheath left groin
 - Prostar XL (ABBOTT) right groin
 - Placement of 14F through the right groin
- 2. Stentgraft implantation**
 - Valiant Navion (MEDTRONIC)
- 3. Final angiography**
- 4. Closure of the right groin**
 - Prostar XL (ABBOTT)
- 5. Closure of the left groin**
 - Angioseal (ST. JUDE)



Case 67 – PAR 01: male, 61 years (D-C)

Branched aortic arch endograft for dissecting aortic arch aneurysm (72 mm)

Operators: S. Haulon, D. Fabre, J. Mougin, L. Freycon, B. Pochulu

Clinical data: 2017: Ascending aortic repair
HTA, severe COPD, aneurysmal evolution of the aortic arch false lumen
Previous acute type A aortic dissection open repair

Risk factors: Former smoker

Procedural steps:

- 1. Right groin & bilateral cervicotomy access, 100 U/kg Heparin (Target ACTff1300)**

- R: 7F sheath – advance Terumo in true lumen to ascending aorta
- Right femoral vein: Rapid pacing catheter advanced to right ventricle/test
- RCCA: 6F sheath, advance wire and BER catheter to aortic valve
- LCC: 6F sheath, advance Pigtail catheter against aortic valve

- 2. R: Terumo advanced through aortic valve with AL-2 catheter into the LV**

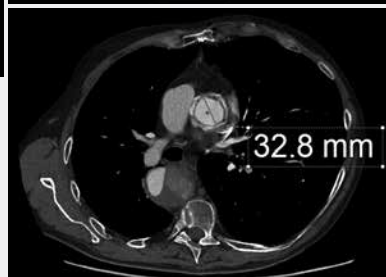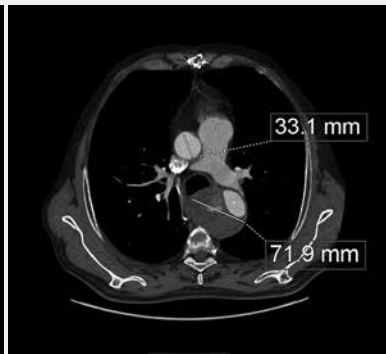
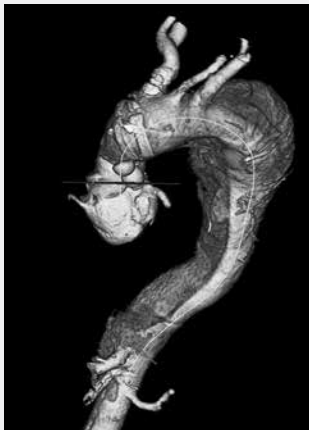- replace by Lunderquist/dilators (up to 22F)
- Markers of the device located under fluoroscopy

- 3. Advance Inner branched device to the ascending aorta**

- nose through aortic valve into left ventricle

- 4. Aortic angiogram to locate coronary arteries and supraaortic trunks**

- Under rapid pacing endograft full deployment (release trigger wires)
- Nose retrieval
- Lunderquist withdrawn in the descending aorta



Case 67 – PAR 01 (cont.): male, 61 years (D-C)**Procedural steps (cont.):**

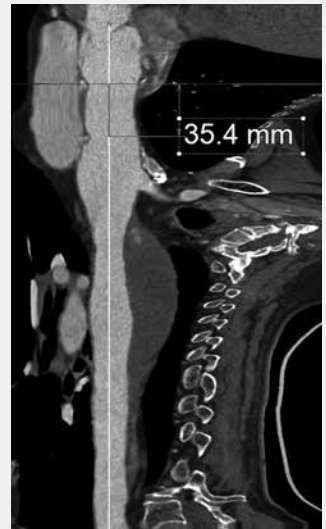5. **RCCA: BER/Terumo to catheterize IT branch**
 - Advance wire through aortic valve
 - Exchange for Rosen wire
 - RIM manoeuver
 - Inflate 12 x 40 balloon in inner branch under fluoroscopy (two perpendicular projections)
 - Angiogram to locate IT bifurcation
 - RCC clamping IT bridging limb is advanced on Rosen wire
 - Deployment of the limb under fluoroscopy
 - 12 x 40 balloon inflation of overlap
 - IA angiogram
 - RCCA repair to restore flow after flushing

6. **LCCA: BER/Terumo to catheterize LCCA inner branch**
 - Exchange for Rosen wire advanced to aortic valve
 - RIM manoeuver
 - Inflate 8 x 40 balloon in inner branch under fluoroscopy (two perpendicular projections)
 - LCC clamping – Covered stent deployment then nitinol stent deployment
 - 10 x 40 balloon inflation of overlap
 - LCCA angiogram
 - LCCA repair to restore flow after flushing

7. **Advance Lunderquist in LSCA preloaded catheter**
 - Retrieve delivery system of A-branch, replace by short 22F sheath
 - Advance 12F 80 cm into LSA branch through 22F sheath over Lunderquist
 - 100 cm BER
 - Terumo wire to catheterise LSA
 - Exchange for Rosen wire
 - Retrieve Lunderquist
 - LSA angiogram to locate vertebral artery origin
 - Deployment of covered stent then nitinol stent
 - 12 x 40 Balloon inflation of overlap
 - LSCA angiogram

8. **TEVAR procedure**
 - Access false lumen
 - Candy Plug implanted in false lumen

9. **Final angiogram**



Case 68 – MUN 08: female, 51 years (G-5)

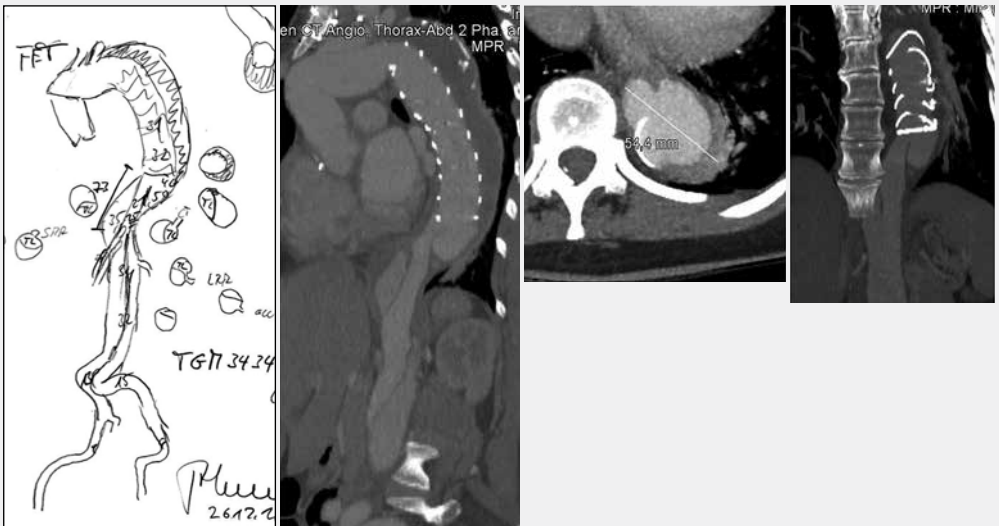
TEVAR-Extension of a frozen elephant trunk in a thoraco-abdominal aortic dissection

Operators: M. Austermann, E. Beropoulos

Clinical data: Art. hypertension

Present state: 2009 acute Type A dissection treated with an open replacement of the asc. aorta. 2018 symptomatic postdissection arch and thoracoabdominal aneurysm treated by reopening of the chest and implantation of a frozen elephant trunc. Now still back pain and a big entry tear at the end of the FET

- Procedural steps:**
1. Percutaneous approach both groins
5 F sheath left groin. Prostar XL (ABBOTT) right groin
Placement of 14F later 22F Dry-Seal-sheath (GORE) through the right groin
 2. Cannulation of the true lumen (stiff TERUMO wire) and changing for a Lunderquist wire(COOK)
 3. Implantation of the GORE C-TAG endograft with the active control system step by step
 4. Positioning of the graft and deployment up to 50% diameter
 5. Angiography, correction of the graftposition and the C-arm angulation
If necessary angulation of the graft
 6. Complete deployment of the graft and possibly some more angulation in order to achieve ideal wall apposition
 7. Final angiography



Case 69 – LEI 24: male, 67 years, (R-H)

MISACE: Minimal Invasive Segmental Artery Coil Embolisation

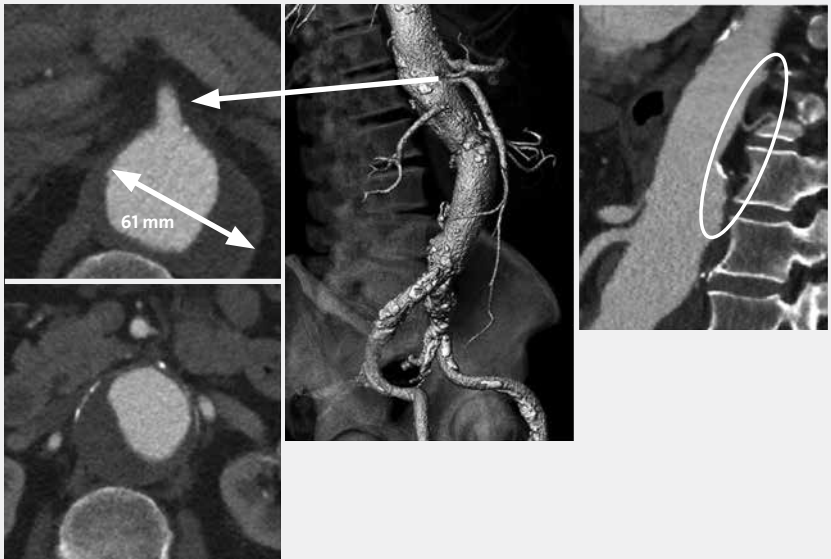
Operators: A. Schmidt, A. Fischer

Clinical data: Thoracoabdominal aneurysm (max. diameter 61mm), progressive (41mm 2014)
Open repair of an infrarenal aortic aneurysm 10/2014
CAD, PTCA 2014

Risk factors: Arterial hypertension

CT: Progressive aneurysm, max. diameter 61 mm

Important items: Endovascular repair planned (CMD, COOK)
Staged segmental artery coilembolisation
for prevention of spinal-cord-ischemia planned



Procedural steps:

1. **Right femoral approach**
 - 6F 25 cm sheath (TERUMO)
2. **Angiography**
of the segmental arteries Th 12 - Th 10 bilateral
Selection of the arteries to be embolized during the first session
3. **Coilembolisation**
 - IMA 6F guiding catheter (MEDTRONIC)
 - SIM-I 5F diagnostic catheter (CORDIS-CARDINAL HEALTH)
 - 0.014" PT2 guidewire (BOSTON SCIENTIFIC)
 - Progreat Micro Catheter System 2.7F 130 cm (TERUMO)
 - Micro-Coils (COOK)

Case 70 – MUN 09: male, 74 years (G-B)

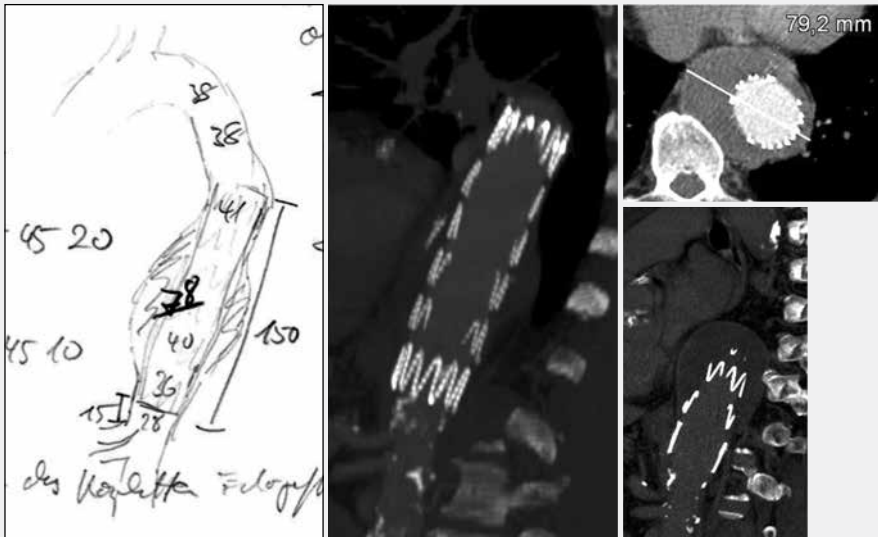
Redo-TEVAR because of loss of seal and growing aneurysm sack

Operators: M. Austermann, E. Beropoulos

Clinical data: Renal impairment, stent-PTA RRA 2014, carotid artery stenosis right side, CAD, DM 2

Important items: Open repair of the abdominal aorta 2009, TEVAR 2013

- Procedural steps:**
1. Percutaneous approach both groins. 5F sheath left groin. Prostar XL (ABBOTT) right groin. Placement of 14F later 24F Dry-Seal-sheath (GORE) through the right groin
 2. Implantation of the GORE C-TAG endograft with the active control system.
 3. Positioning of the graft and deployment up to 50% diameter.
 4. Angiography, correction of the graftposition and the C-arm angulation. If necessary angulation of the graft.
 5. Complete deployment of the graft and possibly some more angulation in order to achieve ideal wall apposition.
 6. Final angiography, if needed post-dilation.
 7. Closure of the right groin using Prostar XL (ABBOTT). Angioseal (ST. JUDE) left groin.



Case 71 – PAR 02: female, 72 years (V-M)

FEVAR for type 4 thoraco abdominal aortic aneurysm**Operators:** S. Haulon, D. Fabre, J. Mouglin, L. Freycon, B. Pochulu**Clinical data:** Type 2 diabetes, HTA, obesity (BMI >30)
Incisional hernia, splenectomy**Procedural steps:****1. L: Advance 16F 30cm GORE Dryseal sheath in the LCFA over Lunderquist**

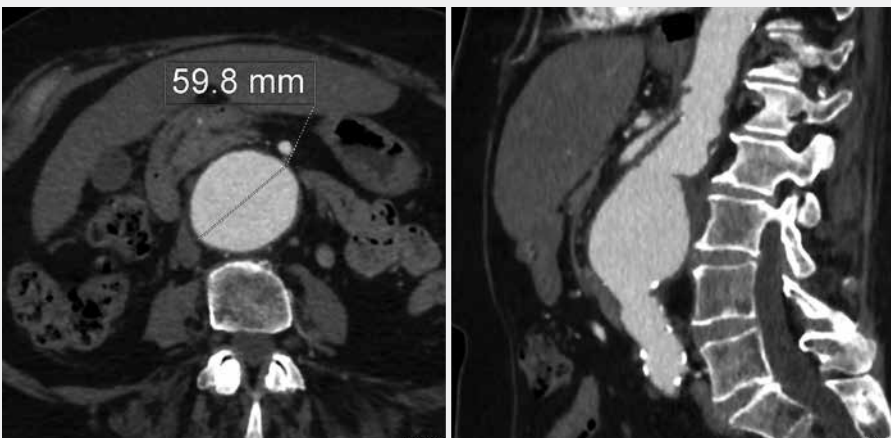
- 2 x 6F 55 cm COOK Ansel sheaths
- 100 U/kg Heparin (Target ACTffl250)
- L (through one of the 6F): advance long pigtail catheter
- R: 10F sheath
- Lunderquist (dilators up to 20)

2. Fluoroscopy to locate fenestrations gold markers

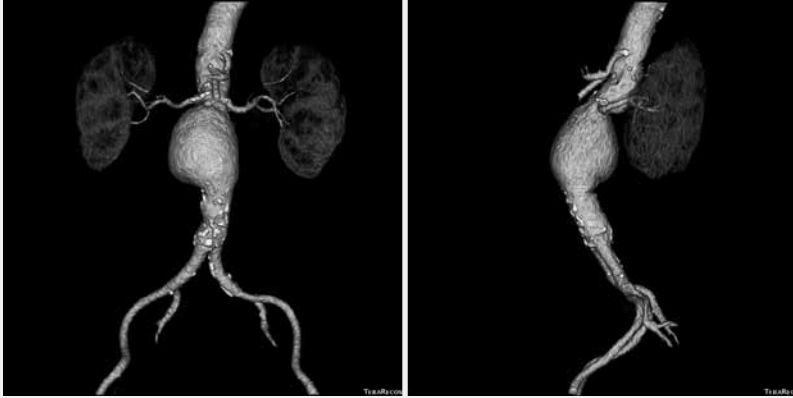- R: Advanced fenestrated endograft
- Aortic angiogram
- Fenestrated endograft deployment

3. R: Rosen wire advanced through preloaded catheter

- Exchange preloaded catheter for a 6F 90 cm COOK Ansel sheath
- Exchange Rosen for a V18 300 cm wire
- Retrieve 6F to the level of the fenestration
- Retrieve the 6F dilator
- Puncture valve
- DAV + Terumo Roadrunner through 6F for renal artery catheterisation
- Renal angiogram
- Exchange Terumo for Rosen
- Retrieve V18 wire
- Advance 6F into the renal artery
- Advance BENTLEY Begraft bridging stent to parking position

4. Same for controlateral renal artery

Case 71 – PAR o2 (cont.): female, 72 years (V-M)



Procedural steps (cont.):

5. **L: Through 6F sheath advance BER + Terumo to catheterize fenestrated endograft lumen**
 - Advance 6F below the fenestration (SMA/CT)
 - USL + Terumo Roadrunner through 6F sheath to catheterise target vessel (SMA/CT)
 - Vessel angiogram
 - Exchange Terumo for Rosen wire
 - Advance 6F into target vessel
 - Advance BENTLEY Begraft bridging stent to parking position
6. **R: Release diameter-reducing ties**
 - Proximal and distal attachments
 - Nose retrieval under fluoroscopy
7. **R: Renal artery stent deployment (3-4 mm protruding in aortic lumen) after 6F retrieval**
 - Flare the aortic portion of stent with 9-20 mm balloon
 - Advance 6F back into the renal stent
 - Angiogram
 - same for left renal artery
8. **L: SMA/CT stent deployment (3-4cm protruding in the aortic lumen) after 6F retrieval**
 - Flare the aortic portion of stent with 10-20 mm balloon
 - Advance 6F in the SMA
 - CT stent
 - Angiogram (SMA: exchange Rosen for terumo wire)
9. **R: Remove nose under fluoroscopy**
 - Remove fenestrated device delivery system

L: Withdraw 6F sheath in 16F

 - insert and deploy bifurcated device and iliac limbs
10. **CODA balloon to mold overlaps and distal sealing zones**
 - Pigtail catheter
 - Angiogram + non-contrast CBCT

Case 72 – LEI 25: male, 62 years (RT-V)

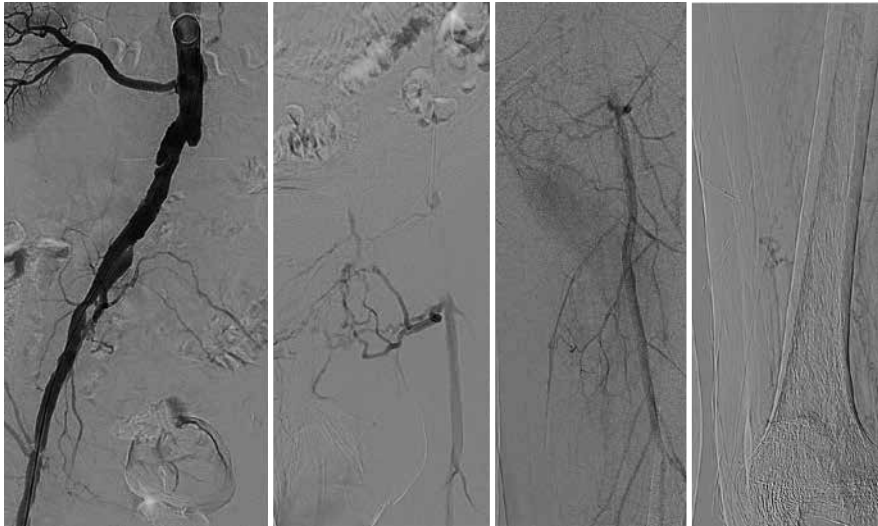
Total occlusion of the left CIA and EIA

Operators: S. Bräunlich, M. Ulrich

Clinical data: PAOD Rutherford class 3, severe claudication both calves, walking capacity 50 m, ABI left 0.3, ABI right 0.6
COPD, biliar carcinoma 12/17

Risk factors: Arterial hypertension, hyperlipidemia, nicotine abuse (40PY)

Angiography: Occlusion of left CIA and EIA and of both SFA



Procedural steps:

1. **Left femoral access**
 - 7F 25 cm Radiofocus Introducer (TERUMO)
 - 0.035" SupraCore guidewire 300 cm (ABBOTT)

Left brachial approach:

 - 6F 90 cm Check-Flo Performer (COOK)
2. **Antegrade and retrograde guidewire passage**

brachial:

 - 5F Judkins Right diagnostic catheter 125 cm (CORDIS/CARDINAL HEALTH)

from femoral:

 - 5F Multipurpose diagnostic catheter 80 cm (CORDIS/CARDINAL HEALTH)
 - 0.035" stiff angled guidewire, 260 cm (TERUMO)
3. **Predilatation and stenting of the aorto-iliac bifurcation**
 - Ultraverse or Dorado balloon (BARD)
 - LifeStream covered stent 8/58 mm bilateral common iliac arteries in kissing-technique (BARD)
 - Covera Plus vascular covered stent for the external iliac artery (BARD)

Case 73 – BK 03: male, 54 years (D-K)

Directional atherectomy of DFA origin and recanalization of SFA flush occlusion

Operators: T. Zeller

Clinical data: POAD Fontaine IIb / Rutherford 3 right leg, walking distance < 100 m
Unsuccessful recanalisation attempt December 2018 in referring clinic
ABI: 0.6/1.0

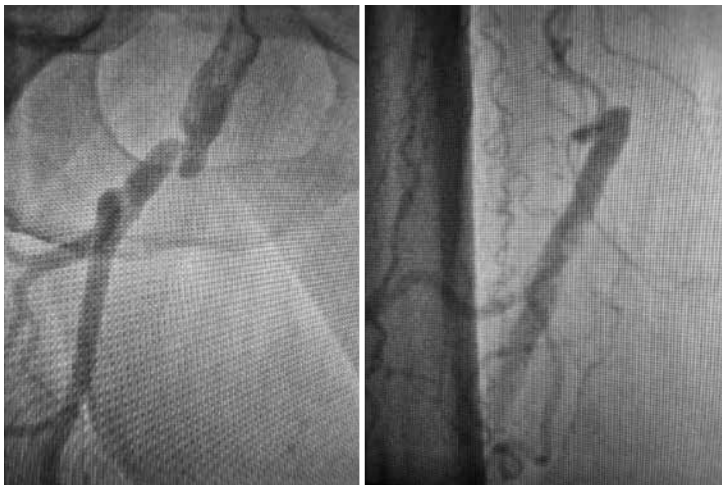Risk factors: Smoker, hypercholesterinemia

Angiogram: 80% ostial DFA stenosis, flush occlusion of SFA origin, reconstitution distal SFA

Procedural

steps:

1. **Access**
 - 7F cross-over Sheath (TERUMO)
2. **Directional atherectomy of DFA origin**
 - SilverHawk (MEDTRONIC)
3. **Recanalisation of SFA**
 - Woodpecker (UPSTREAM MEDICAL)
4. **Placement of a filter protection device into the popliteal artery**
 - Spider (MEDTRONIC)
5. **DA of SFA**
 - SilverHawk (MEDTRONIC)
6. **DCB angioplasty**
 - IN.PACT Pacific (MEDTRONIC)
7. **Stent on indication**
 - BioMimics (VERYAN/OTSUKA)



Case 74 – ABT 03: male, 73 years (C-M)

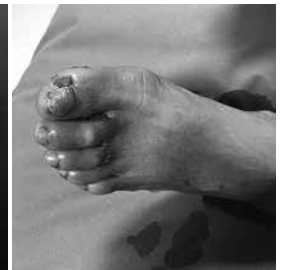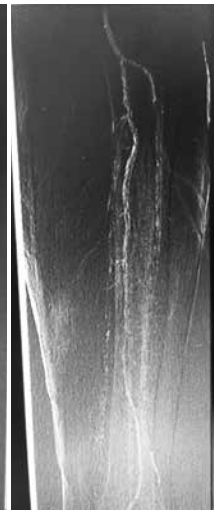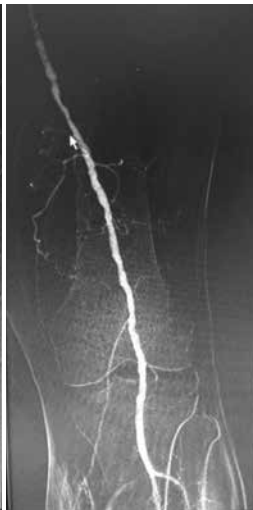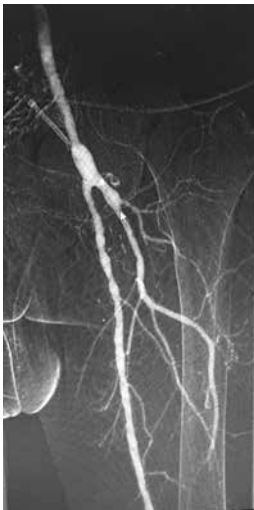
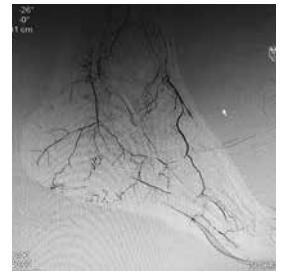Multilevel SFA and BTK/BTA

Operators: M. Manzi, S. Ferreira Diaz

Clinical data: Left Ulceration of 1° toe TcPO₂ = 12 mmHG
Mid SFA stenosis and BTK/BTA occlusion

Risk factors: DM, ESRD, dialysis

- Procedural steps:**
1. **Antegrade CFA US guided puncture**
 - 11 cm sheath (TERUMO)
 2. **SFA and AT**
 - 0,018 V18 CW (BOSTON SCIENTIFIC) wiring and SFA stenosis 5 mm POBA
 - 1:1 DEB + bail-out spot stenting
 3. **Intraluminal/subintimal AT and pedal artery recanalization**
 - 0.014" Command ES (ABBOTT VASCULAR)
 - Retrograde when failure
 4. **Angioplasty**
 - 2.5/3 mm POBA Bard Ultraverse
 - DEB discussion
 5. **US guided closure**
 - 6F Angio-Seal



Case 75 – LEI 26: male, 62 years (S-S)

Extremely calcified SFA CTO left, "pave and crack"-technique

Operators: A. Schmidt, M. Ulrich

Clinical data: PAOD Rutherford Class 3, severe claudication left, walking capacity 50m, ABI left 0.45
 PTA both CIA 2012, multiple interventions right,
 failed recanalization attempt left SFA 12/2018
 CAD, CABG 2012, atrial fibrillation, renal impairment

Risk factors: Arterial hypertension, hyperlipidemia, former smoker (30PY)

Angiography: During PTA right 11/17: occlusion of the left SFA and popliteal artery

Procedural steps:

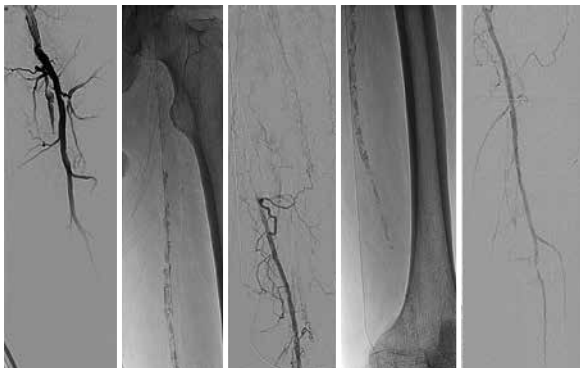- 1. Right groin retrograde and cross-over approach**
 - IMA 5F diagnostic catheter (CORDIS/CARDINAL HEALTH)
 - 0.035" soft angled Radiofocus guidewire, 190 cm (TERUMO)
 - 0.035" SupraCore guidewire 190 cm (ABBOTT)
 - 7F 55 Check-Flo Performer Sheath, Raabe Modification (COOK)
- 2. Antegrade guidewire passage**
 - 0.035" Stiff angled glidewire, 260 cm (TERUMO)
 - CXC 0.035" support catheter, 135 cm (COOK)
 - GoBack Crossing-Catheter (UPSTREAM-PERIPHERAL)
- 3. Retrograde guidewire passage**

Access via the proximal anterior tibial artery:

 - 9 cm 20 Gauge Spinal Needle (BD)
 - 0.018" V-18 Control guidewire, 300 cm (BOSTON SCIENTIFIC)
 - 4F 10 cm Radiofocus Introducer (TERUMO)
 - Pacific Plus 4.0/40 mm balloon, 90 cm (MEDTRONIC)
- 4. PTA and stenting**
 - 6.0/20mm Admiral Xtreme balloon (MEDTRONIC)
 - 7.0/20 Conquest non-compliant high pressure balloon (BARD)

In case of inability to open the balloons fully:

 - Implantation of a Viabahn 6.0/150 mm (GORE)
 - Relining with Supera Interwoven Nitinol stent (ABBOTT)



Case 76 – BK 04: male, 78 years (B-J)

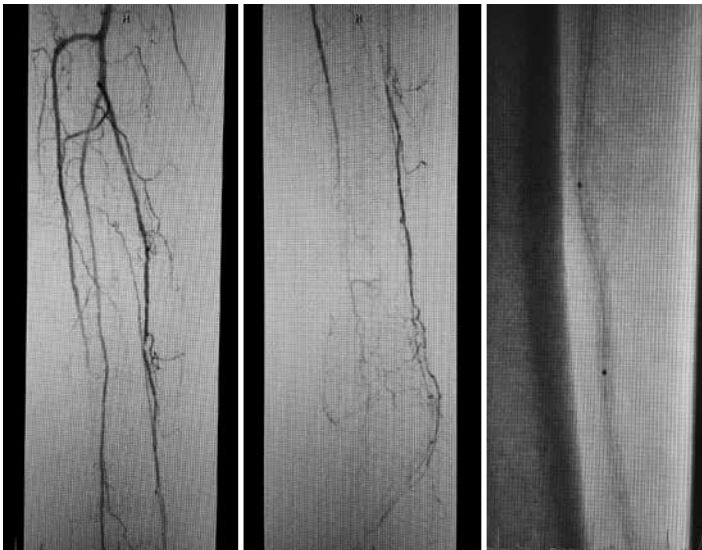
Orbital atherectomy of severely calcified infrapopliteal arteries in progressive CLI

Operators: T. Zeller

Clinical data: PAOD Fontaine IV / Rutherford 5 both legs (toe ulcers, rest pain)
 Unsuccessful balloon angioplasty ATA, ATP and peroneal artery right leg 12.12.2018 & 09/2018
 Balloon angioplasty peroneal artery left leg 07.11.2018
 CAD, MI 1998 and PCI
 Atrial fibrillation, oral anticoagulation
 ABI: non-diagnostic due to media calcification
 TBI: no toe pressure measurable

Risk factors: Arterial hypertension, hyperlipidemia
 CKD stage III

- Procedural steps:**
1. **Antegrade femoral access (6F, Avanti, Cordis)**
 - 6F, Avanti (CORDIS)
 2. **Guiding catheter**
 - VistaBrite Tip, STR (CORDIS)
 3. **Lesion crossing**
 - 0.014" guidewire
 4. **Diamondback atherectomy (CSI)**
 5. **DCB angioplasty**
 - Lithos (ACCOTEC)



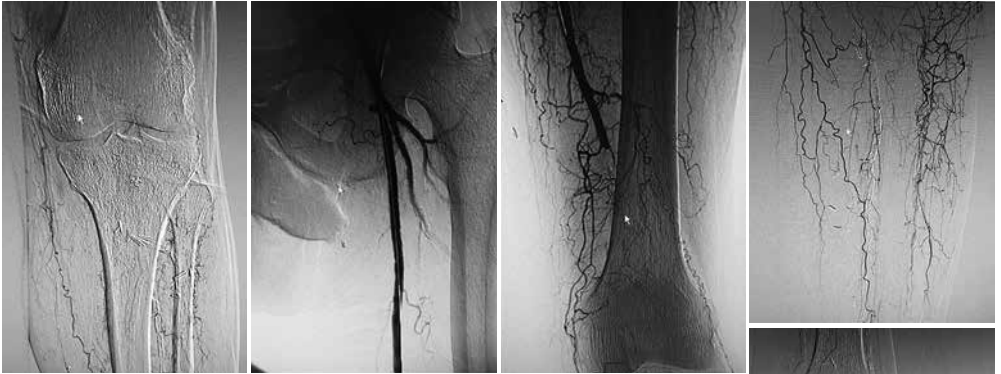Case 77 – ABT 04: male, 81 years (L-N)

Percutaneous AVF in no option patients for foot veins arterialization

Operators: M. Manzi, S. Fereire Diaz

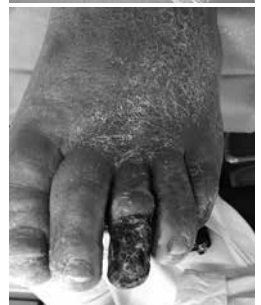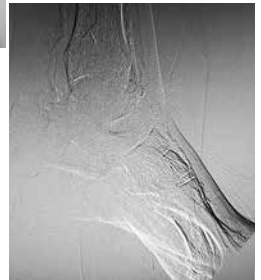Clinical data: Gangrene of III and ulceration of IV toes
Previous twice occluded fem-pop by-pass
Failed attempts of endovascular recanalization

Present state: DM, ischemic cardiac disease
Popliteal occlusion and BTK/BTA occlusion



Procedural steps:

1. **Antegrade US puncture**
 - 6F 11 cm sheath deployment (TERUMO)
2. **Retrograde distal leg vein (posterior tibial vein) US puncture**
 - 6F 11 cm sheath deployment (TERUMO)
3. **Guidewires**
 - Retrograde 0.018 vein wiring
 - Antegrade 0.014 arterial wiring
4. **AVF level identification**
5. **Retrograde in-vein balloon inflation and antegrade arterial Outback deployment and balloon puncture**
6. **Antegrade vein wiring and valves penetration to foot Venous anatomy evaluation**
7. **Dilatation**
 - Venous non compliant Dorado (BARD) POBA dilatation and valves rupture
8. **Stenting**
 - Proximal Covered Bard Fluency SES deployment
9. **US guided closure**
 - 6F Angio-Seal



Case 78 – LEI 27: female, 75 years (B-R)

Calcified BTK CTOs left, CLI

Operators: A. Schmidt, S. Bräunlich

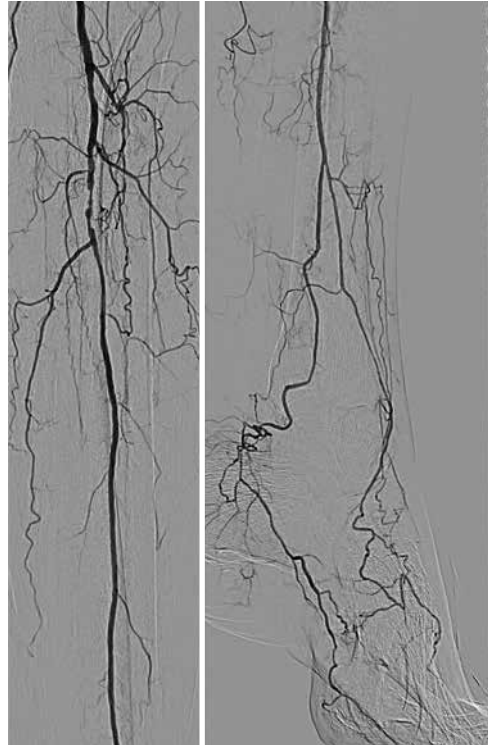
Clinical data: PAOD Rutherford class 5, forefoot and D2-ulcerations, severe claudication and restpain, mediascleoris, ABI left >1.3
PTA left AF 12/18, failed antegrade recanalization of the left ATA
Atrial fibrillation, renal impairment G2

Risk factors: Arterial hypertension, hyperlipidemia, diabetes mellitus type 2

Procedural

steps:

1. **Left groin antegrade approach**
 - 6F 55 cm Flexor Check-Flo sheath, Raabe Modification (COOK)
2. **Guidewire passage attempt from antegrade of the occlusion**
 - 0.014" Command ES guidewire, 300 cm (ABBOTT)
 - 0.018" 90 cm Seeker support catheter (BARD)
3. **In case of failure retrograde approach via dorsal pedal artery**
 - 2.9F sheath (pedal puncture set) (COOK)
 - 0.014" CTO-Approach Hydro guidewire, 300 cm (COOK)
 - 0.018" CXI support catheter 90 cm (COOK)
 - Advance Micro-Balloon 3.0/120 mm, 90 cm (COOK)
4. **Angioplasty and PTA with DCBs**
 - VascuTrak 2.0/200 mm balloon (BARD)
 - Lutonix-BTK DCB (BARD)
5. **In case of dissections after DCB, provisional placement of nitinol "tacks"**
 - Tack Endovascular System (INTACT VASCULAR)



Case 79 – LEI 28: male, 82 years (H-L)

Multilevel disease right, CLI, severe calcification

Operators: A. Schmidt, M. Ulrich

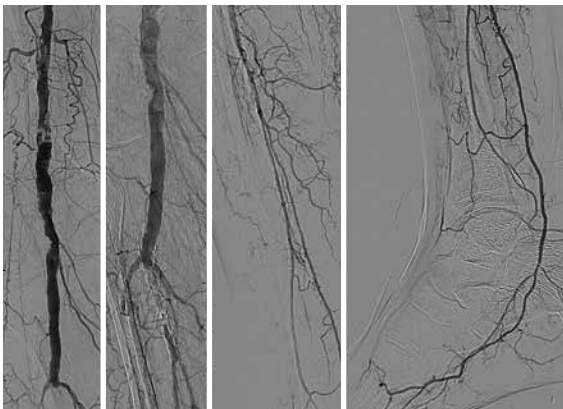
Clinical data: Restpain right, ABI 0.23; walking capacity 20 meters
Rutherford class 4
CAD, NYHA II
PTA left BTK-arteries 12/2018

Risk factors: Arterial hypertension, former smoker

MRA: Aneurysm of the left popliteal artery (35 mm), popliteal occlusion right

Procedural steps:

1. **Right antegrade access**
 - 7F 55 cm Flexor Check-Flo sheath, Raabe Modification (COOK)
2. **Guidewire passage from antegrade**
 - 0.018" Connect 250 T guidewire, 300 cm (ABBOTT)
 - GoBack Crossing-Catheter (UPSTREAM PERIPHERAL)
in case of failure to pass with a GW
3. **Atherectomy and PTA of the distal SFA-lesions**
 - JetStream atherectomy device (BOSTON SCIENTIFIC)
 - Ranger DCB 6 mm (BOSTON SCIENTIFIC)
4. **Guidewire passage of the tibioperoneal-trunk occlusion**
 - 0.018" Connect 250 T guidewire, 300 cm (ABBOTT)
5. **In case of failure: retrograde approach via peroneal artery**
 - 7cm 21 Gauge needle (COOK)
 - Pedal access-kit (COOK)
 - Connect 250T guidewire (ABBOTT)
 - CXI 0.018" Support catheter (COOK)
6. **PTA + Stenting of the TPT**
 - MiniTrek 4.0/20 mm OTW-balloon (ABBOTT)
 - Xience Prime 4.0/38 mm DES (ABBOTT)



LEIPZIG
INTERVENTIONAL
COURSE
2019

L I N C

Friday,
January 25, 2019

Case 80 – MUN 10: male, 68 years, (K-M)

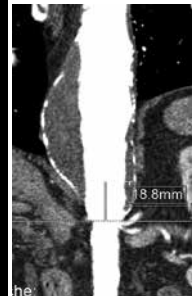
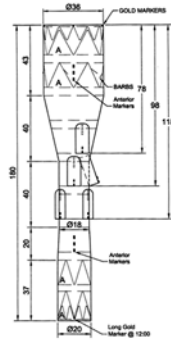
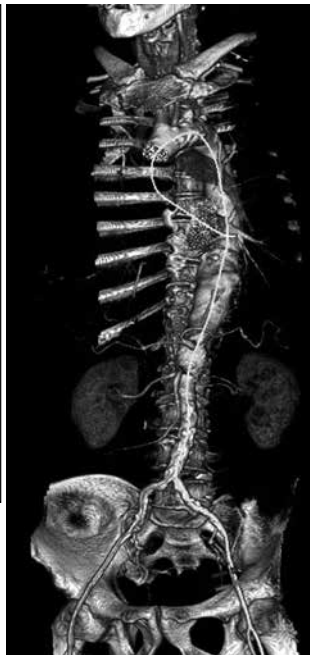
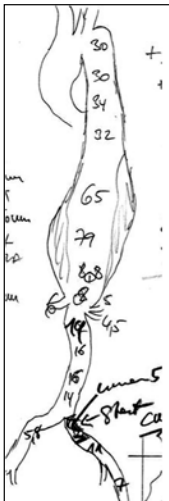
LP-18F-CMD-5-BEVAR for a thoracoabdominal aneurysm type I 79 mm max

Operators: M. Austermann, M. Bosiers, E. Beropoulos

Clinical data: CAD, PTCA 2006 and 2012, atrial fibrillation, art. hypertension, PAD, COPD, left hemicolectomy due to cancer 9/2018

Important items: Stent-PTA left CIA 2001, very narrow iliac arteries

- Procedural steps:**
1. Percutaneous approach both groins with Prostar XL (ABBOTT) 14 F (COOK) both groins
 2. Left axillary access 5F sheath via cut down
 3. Pull through wire between right femoral and axillary access. Pig tail catheter through the left groin for imaging. Registration of the Fusion technology.
 4. Placement of the CMD-branched-endograft (COOK) with 5 branches with help of the Fusion system.
 5. Placement of the 12 F Flexor sheath from above over the pull through wire.
 6. Closure of the groins in order to avoid SCI.
 7. Bridging of all the branches from the axillary access. (Advanta, VBX, VIABAHN)
 8. Closure of the axillary access.



Occlusion of the infrarenal aorta and both iliac arteries, Leriche-syndrome

Operators: A. Schmidt, M. Ulrich

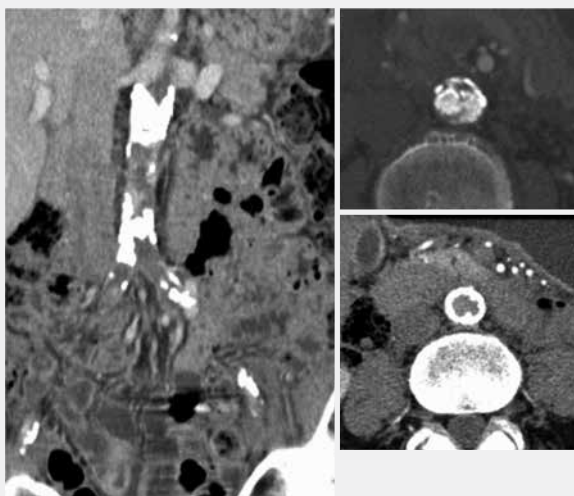
Clinical data: Severe claudication and weakness both legs and buttocks, progressive, Walking capacity 50 meters, Rutherford class 3
CAD, PTCA 2010, chronic heart failure, EF 40%

Risk factors: Art. hypertension, nicotine abuse

CT: Severely calcified occlusion of the infrarenal aorta and iliac arteries

Procedural steps:

1. **Transbrachial bilateral approach**
 - 7F 90 cm Check-Flo-Performer sheath (COOK)
2. **Transfemoral retrograde approach**
 - 8F 25 cm sheath (TERUMO)
3. **Transbrachial guidewire passage**
 - 0.035" Stiff angled guidewire, 260 cm (TERUMO)
 - 6F 100 cm Multipurpose guiding catheter (MEDTRONIC)
 - 5F 125 cm Judkins Right diagnostic catheter (CORDIS-CARDINAL HEALTH)
4. **Snaring of the guidewire-tip from antegrade into the retrograde femoral sheaths**
 - 6F Judkins Right guiding catheter
5. **Renal protection**
 - Implantation of 2 covered stents (LifeStream 7/26 mm, BARD)
6. **PTA of the infrarenal occlusion from retrograde**
 - 6.0/120 mm Admiral balloons (MEDTRONIC)
7. **Implantation of covered stents**
 - BeGraft covered stent (BENTLEY)



Case 82 – LEI 30: male, 72 years (M-S)

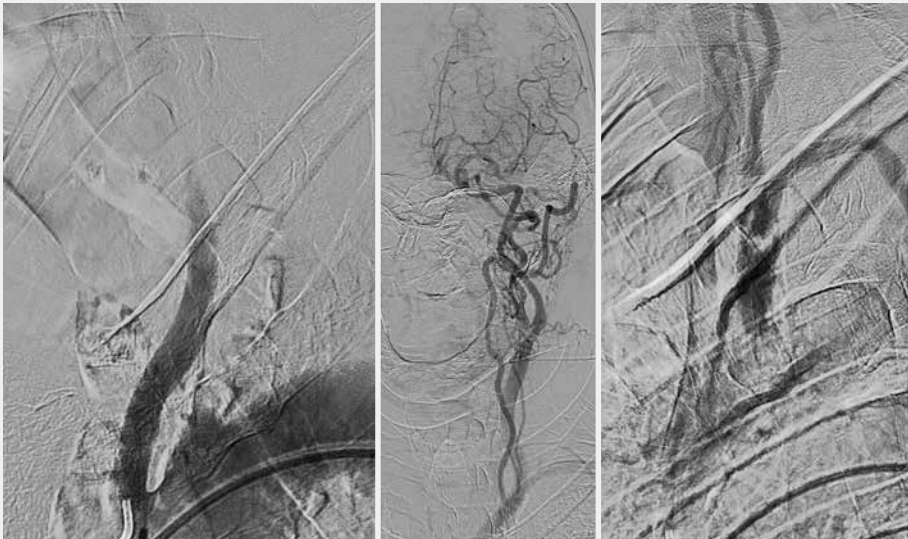
Symptomatic occlusion of the left subclavian artery

Operators: A. Schmidt, S. Bräunlich

Clinical data: Dizziness, syncope 12/2018
Recurrent minor strokes 2017,
Attempt to recanalize the subclavian artery via a femoral approach 12/2018
CAD, PTCA 2012
PAOD, stenting iliac arteries right
Nicotine abuse

Duplex: Occlusion right vertebral artery, high-grade stenosis right internal carotid artery,
Occlusion left subclavian artery

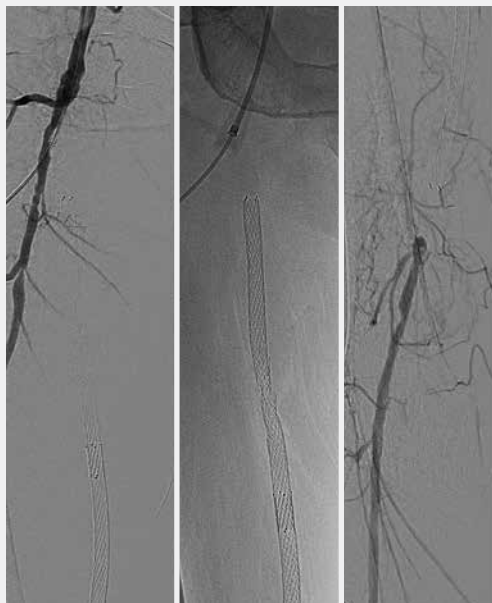
- Procedural steps:**
- 1. Left transbrachial approach**
 - 6F 55 cm Flexor Check-Flo Introducer Raabe-configuration (COOK)
 - 2. Transfemoral retrograde approach**
 - 8F 25 cm sheath (TERUMO)
 - 8F Judkins-Right guiding catheter (MEDTRONIC)
 - 3. Transbrachial and transfemoral guidewire-passage**
 - 0.018" Connect Flex guidewire (ABBOTT)
 - 4. Snaring of the guidewire-tip from antegrade or retrograde and pull-through-wire**
 - 5. PTA and stenting**
 - Pacific 5.0/40 mm balloon (MEDTRONIC)
 - BeGraft covered peripheral stent (BENTLEY)



Case 83 – LEI 31: male, 56 years (G-M)

Reocclusion right SFA**Operators:** A. Schmidt, M. Ulrich**Clinical data:** Severe claudication right calf, ABI 0.67; walking-capacity 150 meters
Rutherford class 3
PTA/Stenting of the infrarenal aorta and iliac arteries 2015
PTA stenting both SFA 2016
PTA of a reocclusion left SFA 12/2018**Risk factors:** Art. Hypertension, heavy smoker**Present state:** Reocclusion right SFA since 2 months, slow onset of symptoms**Procedural steps:**

- 1. Left retrograde and cross-over approach**
 - 7F 40 cm Up&Over sheath (COOK)
- 2. Guidewire passage from antegrade**
 - 0.018" Command 18 guidewire, 300 cm (ABBOTT)
 - GoBack Crossing-Catheter (UPSTREAM PERIPHERAL)
in case of failure to pass with a GW
- 3. Potentially retrograde stent puncture**
- 4. Guidewire passage of the tibioperoneal trunk occlusion**
 - 0.018" Connect 250 T guidewire, 300 cm (ABBOTT)
- 5. Pre-treatment**
 - Rotarex 6F Thrombectomy (STRAUB MEDICAL)
- 6. PTA + Stenting**
 - Ranger DCB within the stents (BOSTON SCIENTIFIC)
 - Evaluation of the stentfracture and potentially relining with Supera stents (ABBOTT)
 - Eluvia DES for the proximal SFA (BOSTON SCIENTIFIC)



Policlinico Abano Terme

Abano Terme, Italy

Marco Manzi

Sandra Fereire Diaz

Heartcenter Bad Krozingen

Clinic for Cardiology and

Angiology

Bad Krozingen, Germany

Thomas Zeller

Elias Noory

Humanitas Gavazzeni Bergamo

Bergamo, Italy

Fausto Castriota

Antonio Micari

St. Gertrauden Hospital

Department of Angiology

Berlin, Germany

Ralf Langhoff

Andrea Behne

David Hardung

Mehmet Boral

OhioHealth Research Institute

Columbus, USA

Gary Ansel

Michael Jolly

Christopher Huff

Mitch Silver

Johann Wolfgang Goethe

University Frankfurt/Main,

**Department of Diagnostic and
Interventional Radiology**

Frankfurt/Main, Germany

N. A. Nour-Eldin

E. Elhawash

N. Naguib

Galway University Hospitals

Galway, Ireland

G. O'Sullivan

M. Mullin

G. Rahmani

University Hospital Jena

**Department of Diagnostic and
Interventional Radiology**

Jena/Gera, Germany

R. Aschenbach

S. Witting

R. Drescher

F. Bürckenmeyer

I. Diamantis

T. Franiel

University Hospital Leipzig,

Department of Angiology

Leipzig, Germany

Dierk Scheinert

Andrej Schmidt

Sven Bräunlich

Matthias Ulrich

Johannes Schuster

Axel Fischer

Manuela Matschuck

Sandra Düsing

Guest-Operator:

Steven Kum (Singapore)

University Hospital Leipzig,

Department of Vascular Surgery

Leipzig, Germany

Daniela Branzan

St. Franziskus Hospital

Clinic for Vascular Surgery

Münster, Germany

M. Austermann

E. Beropoulis

A. Schwindt

K. Donas

M. Bosiers

S. Mühlenhöfer

Mount Sinai Hospital

New York, USA

P. Krishnan

G. Dangas

V. Kapur

Hopital Marie Lannelongue

Paris, France

S. Haulon

D. Fabre

J. Mougín

L. Freycon

B. Pochulu

Zürich University Hospital,

Clinic for Angiology

Zürich, Switzerland

Nils Kucher

Do Dai Do

