

RECORDED cases Leipzig

“Closing every case safely and confidently”

Andrej Schmidt, MD

Medical Department V - Angiology,
University of Leipzig Medical Center,
Germany

Disclosure

Speaker name: Andrej Schmidt

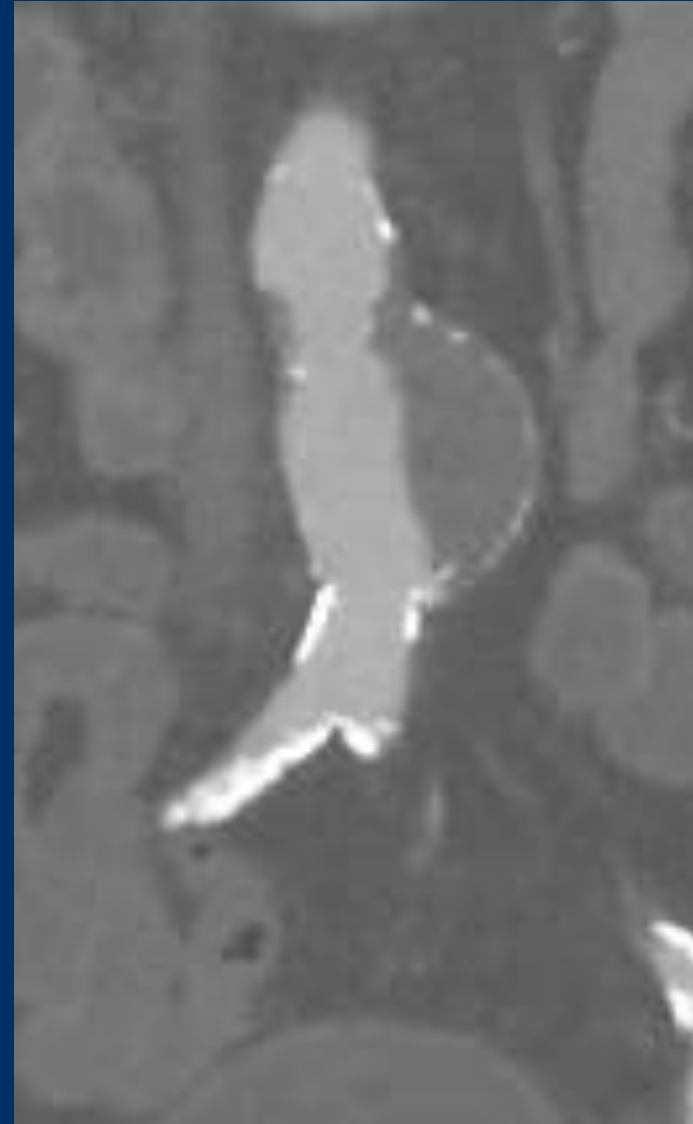
I have the following potential conflicts of interest to report:

Consulting:

Abbott, Bard/BD, Cook, Cordis, Reflow Medical, Upstream Peripheral

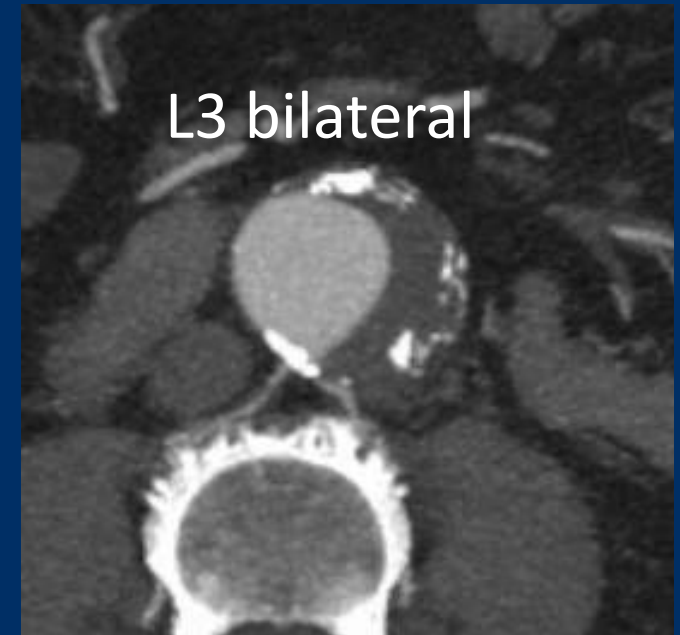
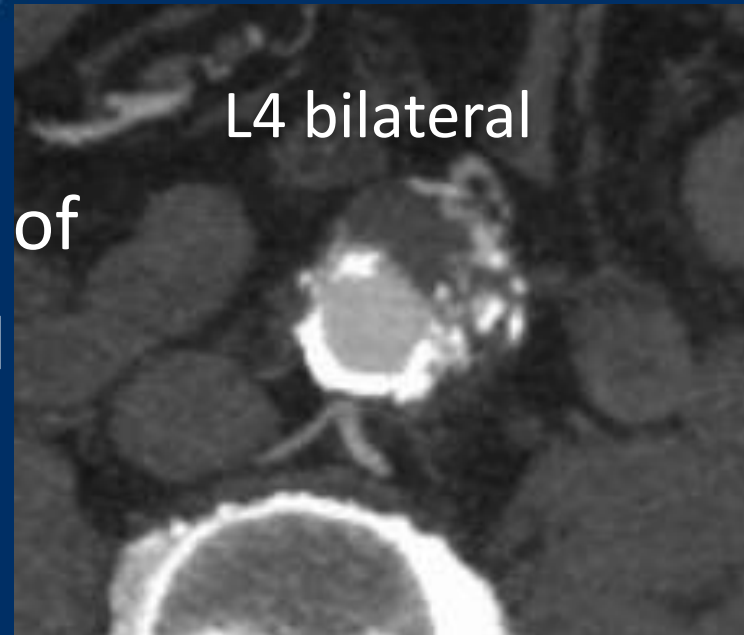Prostyle-Case 1

- Male, 76 years
- Incidental finding of an AAA
- Max. diameter 5,5cm
- CAD, CABG 2010
- Surgery of rectal carcinoma 2018

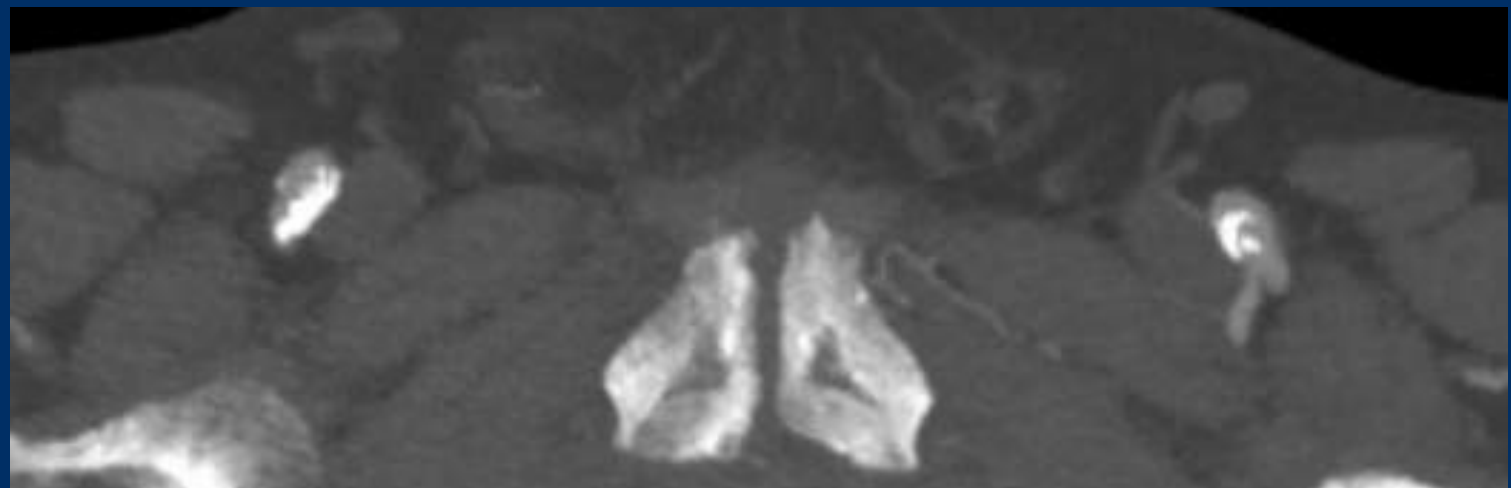

Prostyle-Case 1

- Preemptive coil embolization of segmental arteries planned

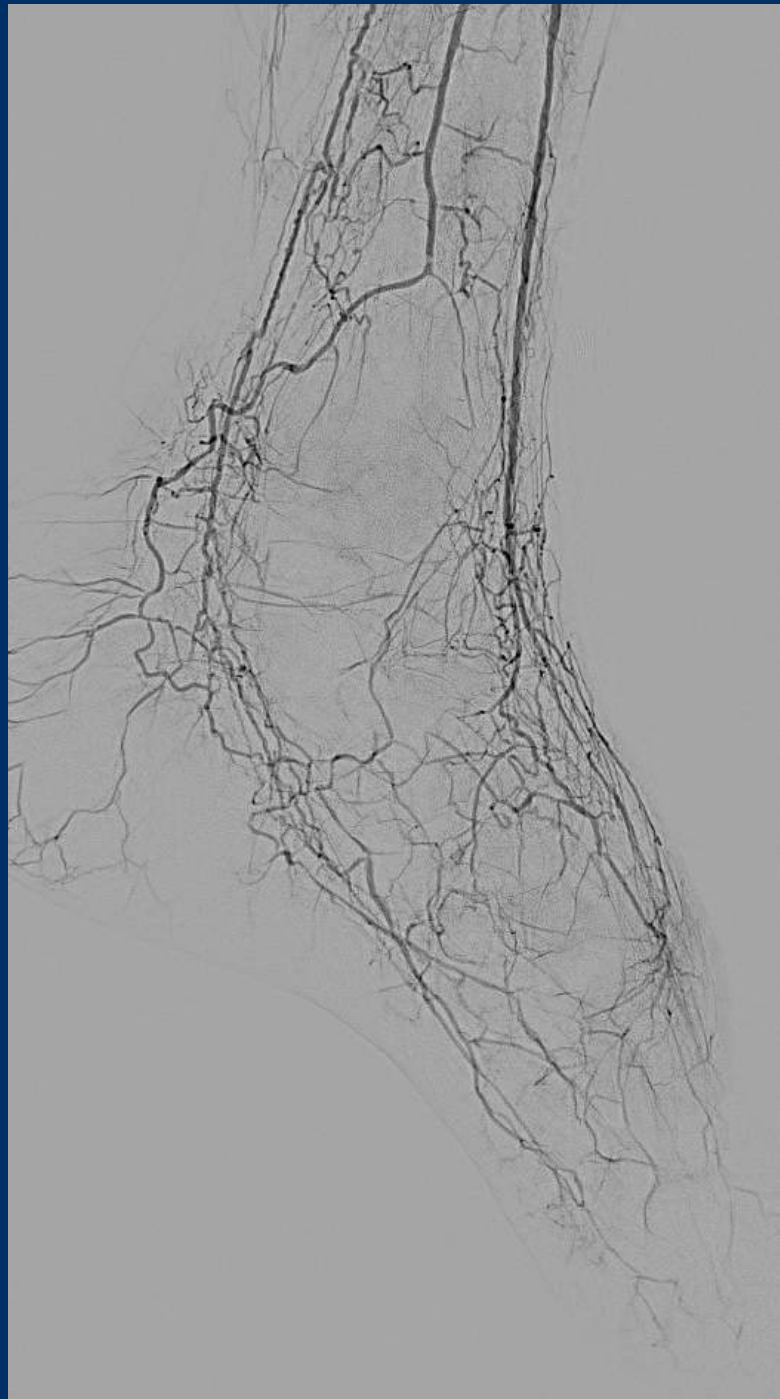
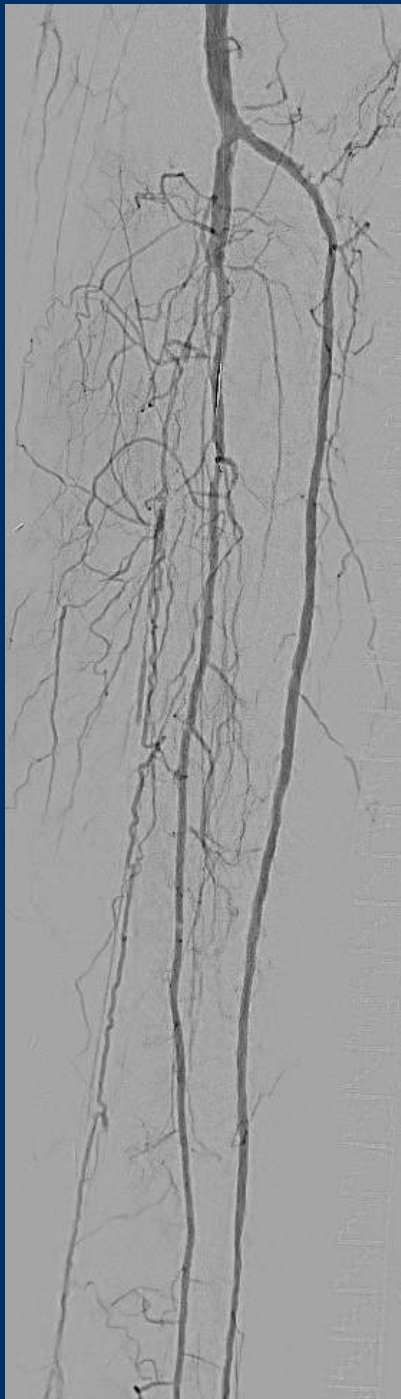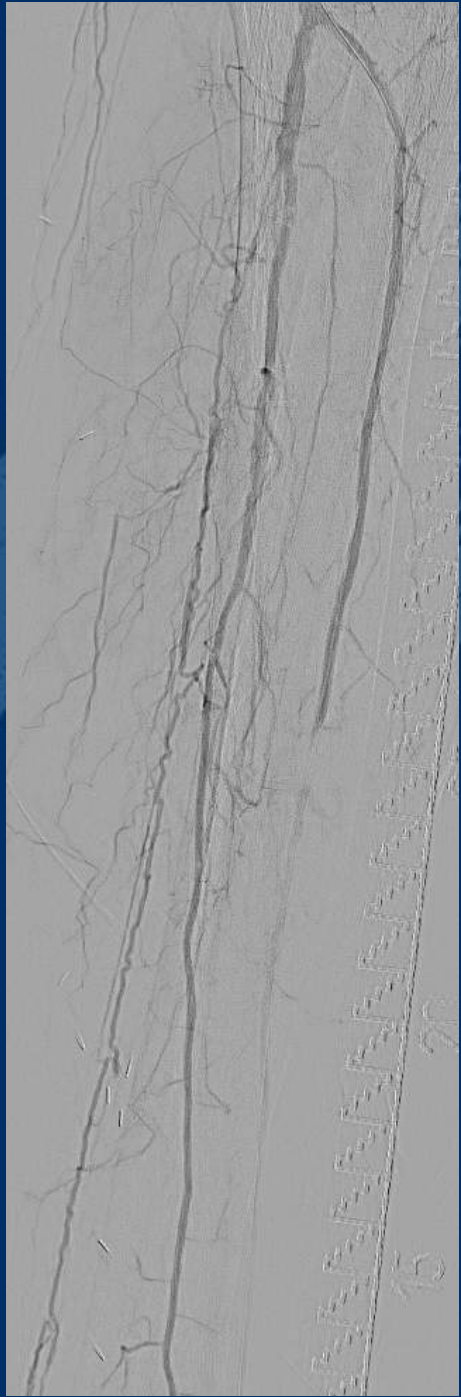


- Access artery calcification



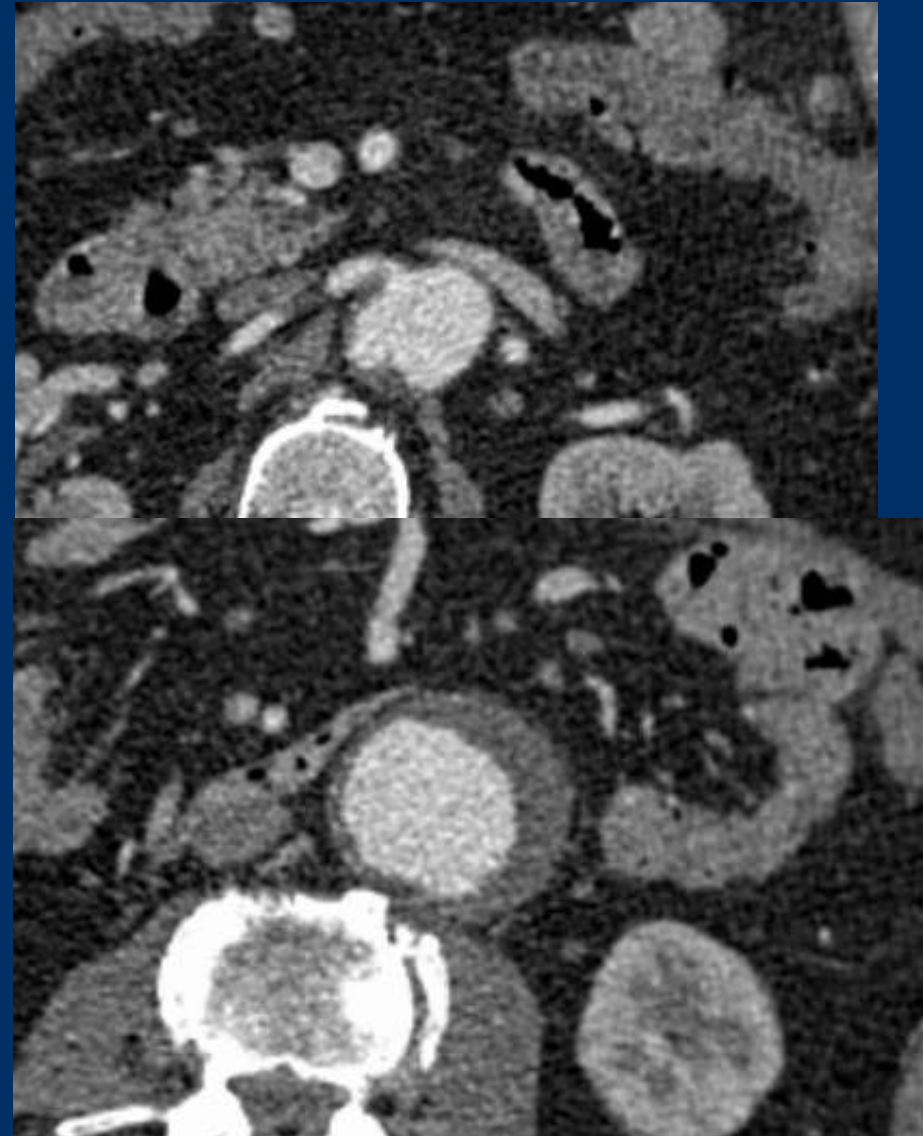
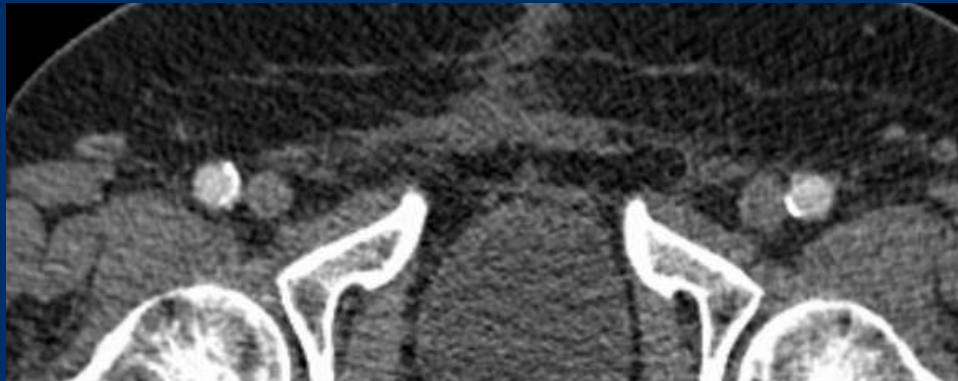Prostyle-Case 2

- Male, 58 years
- CLTI bilateral,
- Dig 4 and 5 ulceration left, restpain right
- ABI right 0.45; left 0.2
- Rutherford 5
- Diabetes mellitus, type 2
- Duplex-sonography:
 - Bilateral BTK-disease



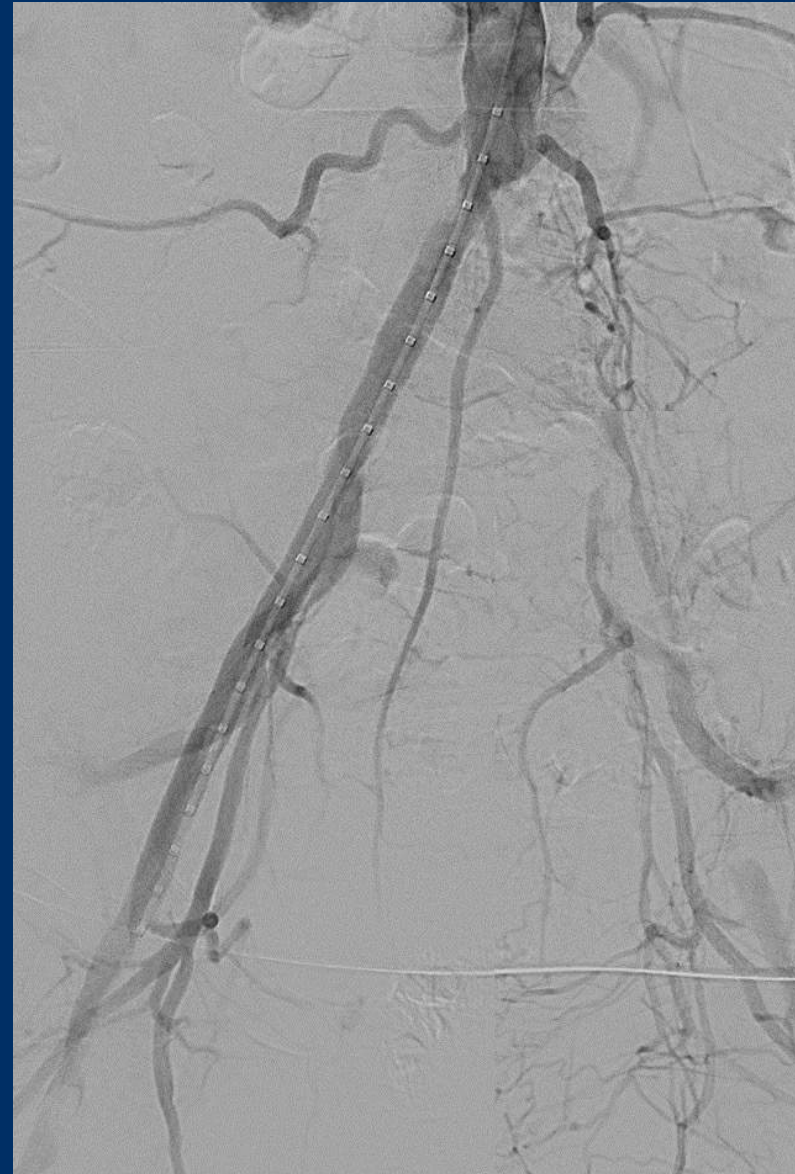
Prostyle-Case 3

- Male, 78 years
- Diameter-Progression of an AAA
- Max. diameter 4,3 → 5,2cm within 6 mo
- CAD, PTCA 2020
- COPD

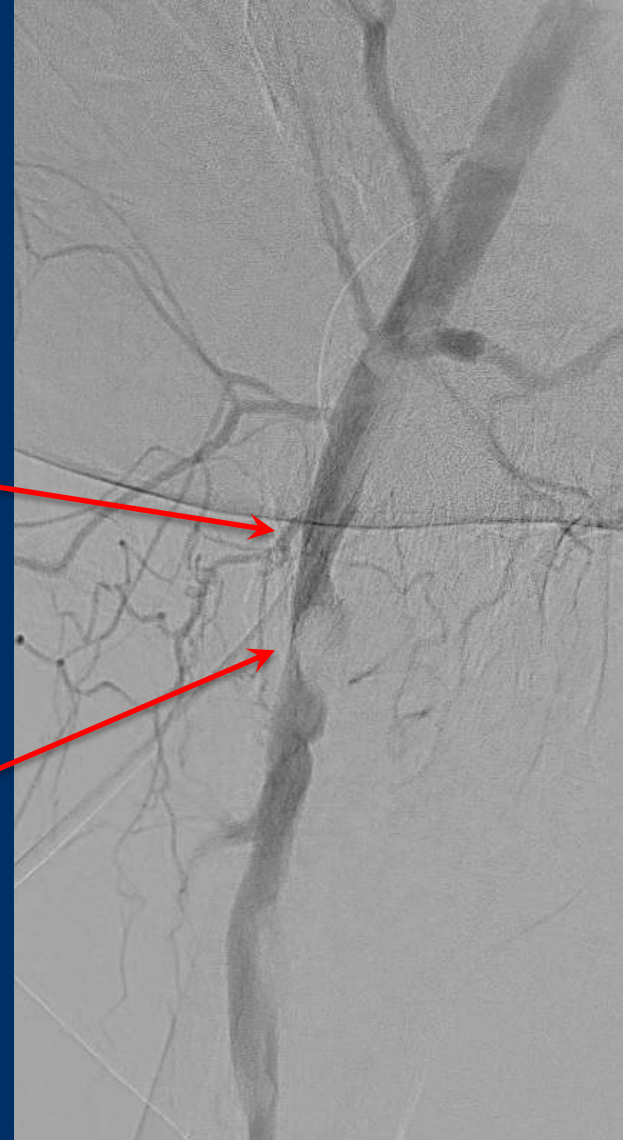
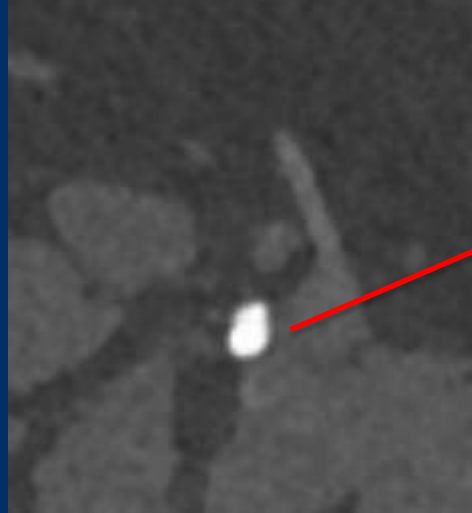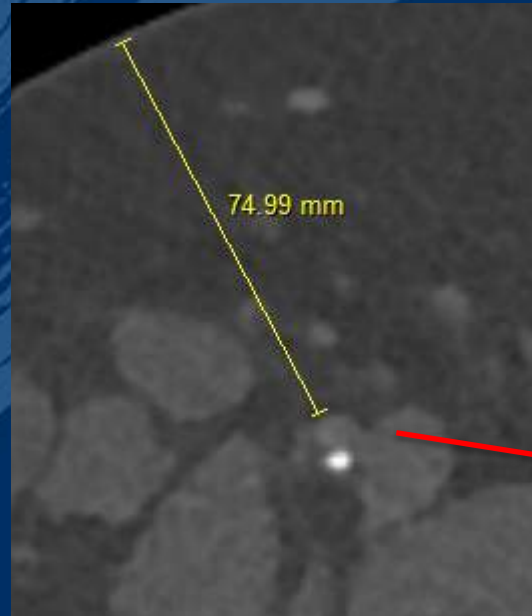


Prostyle-Case 4

- Male, 47 years
- Severe claudication left leg
- Moderate claudication right
- ABI left 0.61; ABI right 0.76
- Adipositas permagna
- Current smoker
- Angio-CT:
 - CTO left common iliac artery
 - High-grade stenosis right CFA

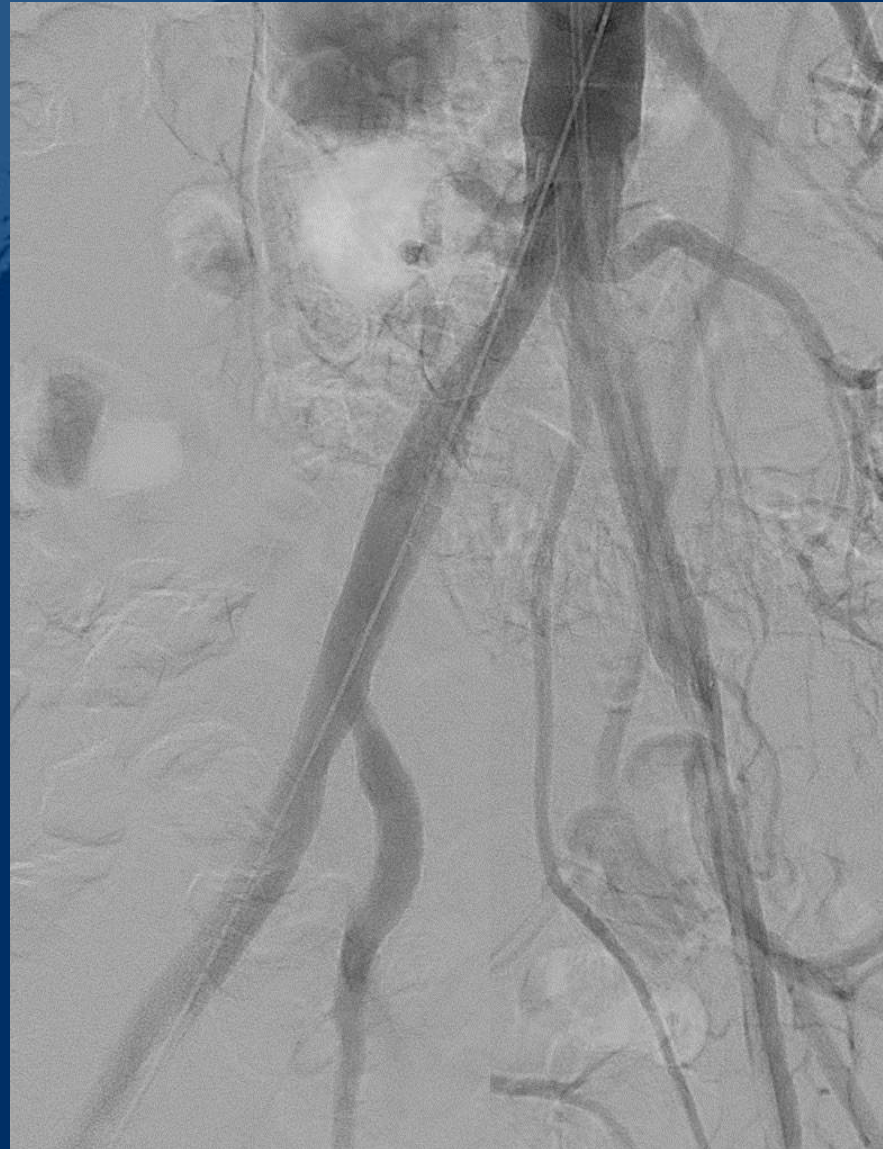

Prostyle-Case 4



Prostyle-Case 4

- Covered stents in kissing-technique
- Manual compression right groin



- Duplex-sonography revealed a high pseudoaneurysm right groin

